

PREVALENCE AND MANAGEMENT OF HERNIAS IN PERITONEAL DIALYSIS PATIENTS

Miguel Ángel García-Ureña,¹ César Remón Rodríguez,² Vicente Vega Ruiz,³ Francisco Javier Carnero Hernández,³ Evaristo Fernández-Ruiz,² Jose Manuel Vazquez Gallego,¹ and Miguel Velasco García³

Department of Surgery,¹ Puerta del Mar University Hospital; Department of Nephrology² and Department of Surgery,³ Puerto Real University Hospital, University of Cádiz, Spain

◆◆ **Objectives:** The aim of this study was to assess the prevalence of hernias before and after the start of continuous ambulatory peritoneal dialysis (CAPD) in patients with end-stage renal disease, and to evaluate the result of a proposed surgical treatment.

◆◆ **Design:** Prospective observational study.

◆◆ **Setting:** University hospital.

◆◆ **Patients:** 122 patients who started CAPD from 1994 to 2000; 26 hernias were diagnosed in 21 (17.2%) patients.

◆◆ **Main Outcome Measures:** Finding of hernias; morbidity associated with catheter insertion and hernia repair; recurrence of hernias.

◆◆ **Results:** 19 hernias were detected in 15 patients (12.3%) before they began CAPD; only 7 hernias were observed while on CAPD. Umbilical (61.5%) and inguinal (26.9%) hernias were the most common. Multiple hernias were detected in 4 patients. Simultaneous repair of hernia and catheter insertion was performed in patients with pre-existing hernias. Under local anesthesia, most patients were operated on with surgical techniques of tension-free hernioplasty using a polypropylene mesh. Only mild post-operative complications were recorded: 3 seromas and 1 hematoma. No fluid leakage was found in our series. There were no long-term complications (infection or recurrence) related to the mesh.

◆◆ **Conclusions:** 73% of hernias in peritoneal dialysis patients occur before starting dialysis. Hernia problems in these high-risk patients can be safely solved using a careful technique with application of tension-free hernioplasty. Most may be repaired under local anesthesia with simultaneous catheter insertion.

Perit Dial Int 2006; 26:198–202

www.PDIConnect.com

KEY WORDS: Hernia; inguinal hernia; umbilical hernia; hernioplasty.

Correspondence to: M.Á. García-Ureña, Avda de la Salinera 26, 11500 El Puerto de Santa María, Spain.

mgarciau@meditex.es

Received 11 February 2005; accepted 30 June 2005.

A number of complications have been described in patients undergoing peritoneal dialysis (PD): infections (peritonitis and exit-site infection), those associated with increased abdominal pressure (hernias, genital swelling, hydrothorax, etc.), and mechanical problems with the catheters (obstruction, leakage, etc.). Many types of hernias have been reported in these patients (1). Both increased intra-abdominal pressure (2) and deteriorated connective tissue (3) seem to be responsible for the high prevalence of these abdominal defects.

Early surgical repair is advised to avoid complications. Before the introduction of biomaterials in hernia surgery, prolonged discontinuation of the continuous ambulatory PD (CAPD) technique and a high recurrence rate were real problems for patients with hernia. The aims of our present study were to assess the prevalence of hernia before initiating and during CAPD and to observe the results of the application of tension-free hernioplasty principles.

PATIENTS AND METHODS

In our hospital, more than 160 catheters for PD have been implanted since 1990. We prospectively studied 122 patients in our CAPD program from 1994 to 2000. Etiology of renal failure was diverse: diabetes (20%), idiopathic (18%), glomerulonephritis (18%), interstitial nephritis (15%), polycystic disease (11%), vascular (9%), others (9%). Before the operation, a careful abdominal examination by nephrologists and two dedicated surgeons was performed to rule out the presence of an asymptomatic hernia. A swan-neck Missouri catheter was used in all cases. The catheters were inserted under local anesthesia and monitored anesthesia care.

In those patients with preexisting hernias, combined hernia repair and catheter insertion was performed. Local anesthesia with monitored anesthesia care was utilized in 16 patients. Spinal ($n = 2$) and general ($n = 1$) anesthesia was applied in other cases because of hernia

size. We used a local preoperative blockade with 1% lidocaine (not exceeding 300 mg) for local anesthesia for both catheter insertion and hernia repair. This procedure was facilitated by the use of a 20-gauge spinal needle. Antibiotic prophylaxis was used in every case.

Surgical repair is performed in every case following tension-free principles of hernia surgery by means of a mesh hernioplasty (4). Whenever possible, peritoneal sacs are dissected and inverted in the abdominal cavity, with care not to open them (Figure 1). The abdominal wall defect, inguinal ring, or umbilical fascia defect are not closed with stitches to avoid generating tension. A polypropylene mesh (Premilene; B. Braun-Aesculap, Tuttlingen, Germany) is utilized.

Lichtenstein technique is carried out for inguinal hernias. A large piece of a non-preshaped mesh is tailored to each patient and extended 2 cm medial to the pubic tubercle, 3 cm above the inferior border of the transverse muscle, and 4 cm lateral to the internal ring. Fixation is secured by a running 00 polypropylene suture of the inferior border and crossing the tails behind the spermatic cord (5). In umbilical hernias with a defect longer than 2 cm, the mesh is always laid on the preperitoneal space. A careful dissection allows closing the peritoneum underneath the mesh to avoid direct contact with abdominal viscera (Figure 1). The mesh is extended at least 3 cm beyond the defect (Figure 2) and fixed with interrupted 000 polypropylene stitches to the ring, without closing the fascia over the defect. In cases of smaller umbilical hernias and epigastric hernias, the preperi-

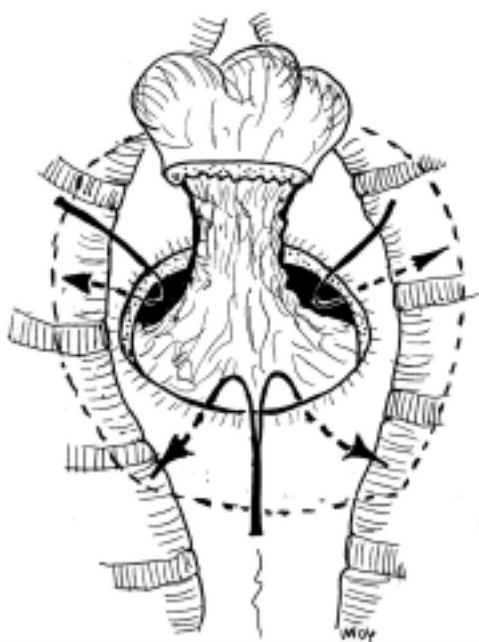


Figure 1 — Dissection of the hernia sac and preperitoneal space in a midline hernia.

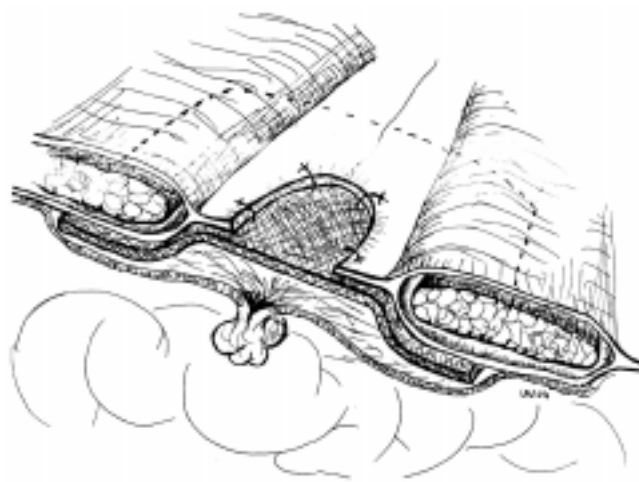


Figure 2 — Coronal section of a preperitoneal mesh hernioplasty for an umbilical hernia.

toneal dissection can be extremely complex; an H hernioplasty is preferred (Figure 3). The mesh is fixed, acquiring an H shape as shown in Figure 3 (6).

The only case of ventral hernia was repaired with retromuscular sublay technique according to Rives (Figure 4) (7). The subcutaneous tissue is approximated and

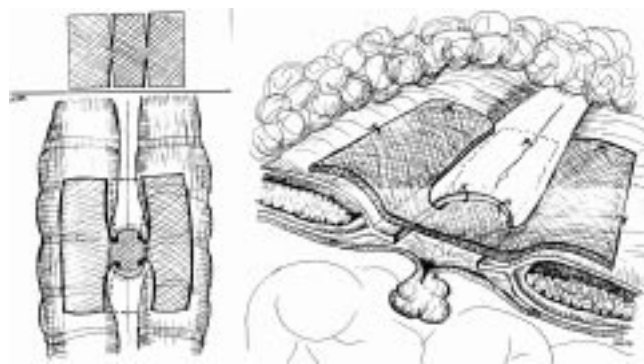


Figure 3 — Coronal section of H mesh hernioplasty for umbilical and epigastric hernia.

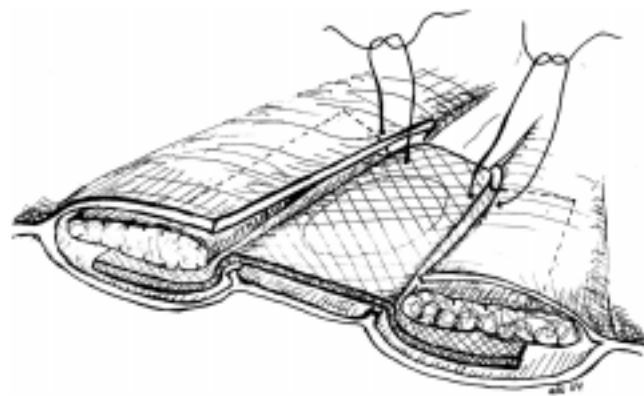


Figure 4 — Coronal section of retromuscular sublay technique for ventral hernia.

attached to the fascia to avoid dead spaces and therefore drains were not routinely used.

Following our protocol, we usually wait 4 weeks before starting CAPD. The catheter is used before 4 weeks in those cases in which clinical condition requires earlier dialysis. Two patients were started on low volume dialysate on the first postoperative day and another two before 14 days. However, we wait only 10 days before restarting the patient on CAPD after a hernia repair. In two cases, the patients could not be transferred to hemodialysis and CAPD was scheduled with low exchange volumes the next day.

RESULTS

We diagnosed 26 hernias in 21 patients (17.2%) from this group of 122 patients. Nineteen hernias (in 15 patients; 12.3%) were detected prior to catheter insertion and 7 hernias (in 6 patients; 4.9%) were seen during CAPD follow-up. The most common hernia was umbilical (61.5%). The characteristics of patients and hernias are shown in Tables 1 and 2. Four patients presented a concomitant abdominal wall defect: 2 patients had an umbilical and an inguinal hernia, another had an inguinal and a femoral hernia on the same side, and another had a bilateral inguinal hernia.

The 122 patients accumulated a total of 2743 months of surveillance. Mean follow-up was 24.4 ± 12.5 months

(range 6 – 39 months). Except for two umbilical hernias, all abdominal wall defects detected during CAPD were surgically corrected because of complications: inability to perform dialysis due to great size (2), incarceration (1), pain (1), and scrotal swelling (1). In this last case, a patent processus vaginalis was diagnosed using peritoneal scintigraphy.

The morbidities associated with repair were 3 seromas and 1 hematoma, which were managed conservatively. No dialysate leak was recorded in our series. We did not detect any exit-site infection during the first 6 months after mesh repair. No complications (persistent seroma, acute or chronic infection, or rejection) have been observed with the use of mesh. No catheter was removed from these 21 patients.

Outcome of the patients with hernias was as follows: 10 (47.6%) remained on CAPD, 3 (14.2%) transferred to hemodialysis, 3 (14.2%) were transplanted, 3 (14.2%) died, 1 (4.7%) had improved renal function, and technique proved inappropriate in 1 (4.7%). Causes of death were attributed to underlying diseases. The length of stay in the dialysis technique was slightly longer in patients with hernial repair (26.8 ± 16.3 months) than in patients without hernias (22.9 ± 10.3 months). To date, no hernia recurrences have been observed in survivors.

DISCUSSION

Hernia is considered a complication of PD. The pathophysiology is based on the concept of increased abdominal pressure (mechanical effect) affecting a weak abdominal wall (metabolic basis).

Prevalence of hernia was higher than in the general population. Reported frequencies range from 10% to 25% (1,8,9). When a thorough examination was performed before starting the patient on CAPD, we detected preexisting hernias in 12.3%, slightly higher than in previous reports (5.5% – 10%) (10–12). Therefore, in our area, two thirds of hernias are present before CAPD. Our findings suggest that increased intra-abdominal pressure might be a secondary or trigger factor in the development of hernias. Their prompt surgical repair may prevent development of future complications. Only 4.9% of patients developed hernia after dialysis.

Umbilical hernia seems to be the most frequent type of hernia in past reports and in our findings (10). Deterioration of connective tissue may be responsible for the loss of substance at the umbilical fascia. We also found an elevated occurrence (19%) of concomitant hernias. Simultaneous hernias and bilateral inguinal hernias seem to be more frequent in this group of patients than in the general population (13).

TABLE 1
Characteristics of Patients

	No hernias	Hernias before CAPD
Age (years)	60±15.5	67±8.5
Sex (M/F)	35/44	8/7
Body mass index	28.2±5.5	29.9±6.5

TABLE 2
Types of Hernias

	Before CAPD	After CAPD	Total
Umbilical	11 (57.8%)	5 (71.4%)	16 (61.5%)
>2 cm	4	2	
<2 cm	7	3	
Epigastric	1 (5.3%)	0	1 (3.8%)
Inguinal	5 (26.3%)	2 (28.6%)	7 (26.9%)
Indirect	3	2	
Direct	2	0	
Femoral	1 (5.3%)	0	1 (3.8%)
Ventral	1 (5.3%)		1 (3.8%)
Total	19 (73%)	7 (27%)	26

Most hernias are asymptomatic, therefore, they can be missed if possible weak points of anterolateral abdominal wall are not carefully explored (10,12,14). Few but severe complications have been described during PD (8,15–17). In our present series, there was also a significant rate of complications with hernias arising during CAPD. In case of genital swelling, scintigraphy, computerized tomography, or magnetic resonance peritoneography may be used to diagnose the patent processus vaginalis or a tear in a hernia sac (1,18–20).

With preexisting hernias, we systematically repair abdominal defects and insert the peritoneal catheter simultaneously, following the experience of Nicholson *et al.* (11). In those cases with simultaneous catheter insertion and hernia, we prefer to first repair the hernia and then implant the catheter in a one-stage procedure. This combined procedure avoids two anesthetic procedures and accelerates the commencement of CAPD.

Local anesthesia facilitates the operation in patients in whom a contraindication to general or spinal anesthesia may exist. In our series, one patient who had a severe myocardopathy had to be operated in two-stage pure local anesthesia surgery: first, umbilical hernia repair and catheter insertion; and second, an inguinal hernia after 10 days. CAPD was begun on the 15th post-operative day without complications. This approach guarantees minimal morbidity in frail patients with numerous underlying diseases.

In midline hernias, in order to avoid complications in the peritoneal cavity, we advocate extraperitoneal surgery with an anterior approach. With special care, the peritoneal sac is dissected, left unopened, and simply inverted. Also, the rapid healing of peritoneal mesothelium would prevent any fluid leakage in case of accidental opening. In these cases, we advise simple repair of the peritoneum with absorbable sutures. Using this technique we did not register fluid leakage after surgical correction, as with other authors with 50 incisional hernias (14) or 11 inguinal hernias (13). The polypropylene mesh is, therefore, always covered by the peritoneum. This situation avoids contact with the abdominal contents and prevents possible infection from dialysis-related peritonitis and fistula formation.

An elevated recurrence rate of hernia (22% – 27%) has been reported after conventional herniorrhaphy (10,21). In the large series by Afthentopoulos *et al.*, umbilical hernia was the type of hernia more prone to relapse (10). This finding supports the poor results found in literature without the use of mesh for midline hernias (22). Polypropylene mesh repair has been recently utilized in hernias of patients on CAPD (8,13). Use of mesh does not seem to increase the incidence of peritonitis or

exit-site infection (8,13). No case of chronic infection or rejection was found in our study. In fact, only one case of chronic mesh infection has been described in the literature so far (23).

In conclusion, more than two thirds of hernias in patients on CAPD arise before starting PD. Umbilical hernia is the most frequent form. Hernia problems in these high-risk patients can be safely solved using careful technique with application of tension-free hernioplasty with a polypropylene mesh. Most can be repaired under local anesthesia with simultaneous catheter insertion.

REFERENCES

1. Bargman JM. Complications of peritoneal dialysis related to increased intraabdominal pressure. *Kidney Int Suppl* 1993; 40:S75–80.
2. Twardowski ZJ, Prowant BF, Nolph KD, Martinez AJ, Lampton LM. High volume, low frequency continuous ambulatory peritoneal dialysis. *Kidney Int* 1983; 23: 64–70.
3. Colin JF, Elliot P, Ellis H. The effect of uraemia upon wound healing: an experimental study. *Br J Surg* 1979; 66:793–7.
4. Lichtenstein IL. *Hernia repair without disability*. 2nd ed. St. Louis: Ishiyaku EuroAmerica; 1986.
5. Amid PK. The Lichtenstein repair in 2002: an overview of causes of recurrence after Lichtenstein tension-free hernioplasty. *Hernia* 2000; 7:13–16.
6. Celdran A, Bazire P, Garcia Urena MA, Marijuan JL. H-hernioplasty: a tension-free repair for umbilical hernia. *Br J Surgery* 1995; 82:371–2.
7. Flament JB, Rives J. Major incisional hernia. In: Chevrel JP, ed. *Hernias and Surgery of the Abdominal Wall*. Berlin: Springer-Verlag; 1998: 128–56.
8. Imvrios G, Tsakiris D, Gakis D, Takoudas D, Koukoudis P, Papadimitriou M, *et al.* Prosthetic mesh repair of multiple recurrent and large abdominal hernias in continuous ambulatory peritoneal dialysis patients. *Perit Dial Int* 1994; 14:338–43.
9. Engeset J, Youngson GG. Ambulatory peritoneal dialysis and hernial complications. *Surg Clin North Am* 1984; 64: 385–92.
10. Afthentopoulos IE, Panduranga RS, Mathews R, Oreopoulos DG. Hernia development in CAPD patients and the effect of 2.5 l dialysate volume in selected patients. *Clin Nephrol* 1998; 49:251–7.
11. Nicholson ML, Madden AM, Veitch PS, Donnelly PK. Combined abdominal hernia repair and continuous ambulatory peritoneal dialysis (CAPD) catheter insertion. *Perit Dial Int* 1989; 9:307–8.
12. del Peso G, Bajo MA, Costero O, Hevia C, Gil F, Diaz C, *et al.* Risk factors for abdominal wall complications in peritoneal dialysis patients. *Perit Dial Int* 2003; 23:249–54.
13. Lewis DM, Bingham C, Beaman M, Nicholls AJ, Riad HN. Polypropylene mesh hernia repair—an alternative

- permitting rapid return to peritoneal dialysis. *Nephrol Dial Transplant* 1998; 13:2488-9.
14. Guzman-Valdivia G, Zaga I. Abdominal wall hernia repair in patients with chronic renal failure and a dialysis catheter. *Hernia* 2001; 5:9-11.
 15. Ralph-Edwards A, Maziak D, Deitel M, Thompson DA, Kucey DS, Bayley TA. Sudden rupture of an indirect inguinal hernial sac with extravasation in two patients on continuous ambulatory peritoneal dialysis. *Can J Surg* 1994; 37:70-2.
 16. Shohat J, Shapira Z, Shmueli D, Boner G. Intestinal incarceration in occult abdominal wall herniae in continuous ambulatory peritoneal dialysis. *Isr J Med Sci* 1985; 21: 985-7.
 17. Chang YP, Chen TW, Chen CP, Ng YY, Yang WC. Inguinal abscess in a CAPD patient secondary to inguinal hernia and repeated episodes of peritonitis: a case report. *Perit Dial Int* 1999; 19:177-8.
 18. Abraham G, Blake PG, Mathews R, Bargman JM, Izatt S, Oreopoulos DG. Genital swelling as a surgical complication of continuous ambulatory peritoneal dialysis. *Surg Gynecol Obstet* 1990; 170:306-8.
 19. Juergensen PH, Rizvi H, Caride VJ, Kliger AS, Finkelstein FO. Value of scintigraphy in chronic peritoneal dialysis patients. *Kidney Int* 1999; 55:1111-19.
 20. Twardowski ZJ, Tully RJ, Ersoy FF, Dedhia NM. Computerized tomography with and without intraperitoneal contrast for determination of intraabdominal fluid distribution and diagnosis of complications in peritoneal dialysis patients. *ASAIO Trans* 1990; 36:95-103.
 21. Wetherington GM, Leapman SB, Robison RJ, Filo RS. Abdominal wall and inguinal hernias in continuous ambulatory peritoneal dialysis patients. *Am J Surg* 1985; 150: 357-60.
 22. Velasco MA, Garcia-Urena MA, Hidalgo M, Vega V, Carnero F. Current concepts on umbilical hernia. *Hernia* 1999; 3:233-9.
 23. Abraham G, Nallathambi MN, Bhaskaran S, Srinivasan L. Recurrence of abdominal wall hernias due to failure of mesh repair in a peritoneal dialysis patient. *Perit Dial Int* 1997; 17:89-91.