Ernie, comunicazioni peritoneo-pleuriche e peritoneo-vaginali: come diagnosticare e correggere queste complicanze.

Matthias Zeiler

Ernie, comunicazioni peritoneo-pleuriche e peritoneo-vaginali, leakage, pressione intraperitoneale: come diagnosticare e correggere queste complicanze.

Matthias Zeiler

La natura è debole

Le debolezze della natura

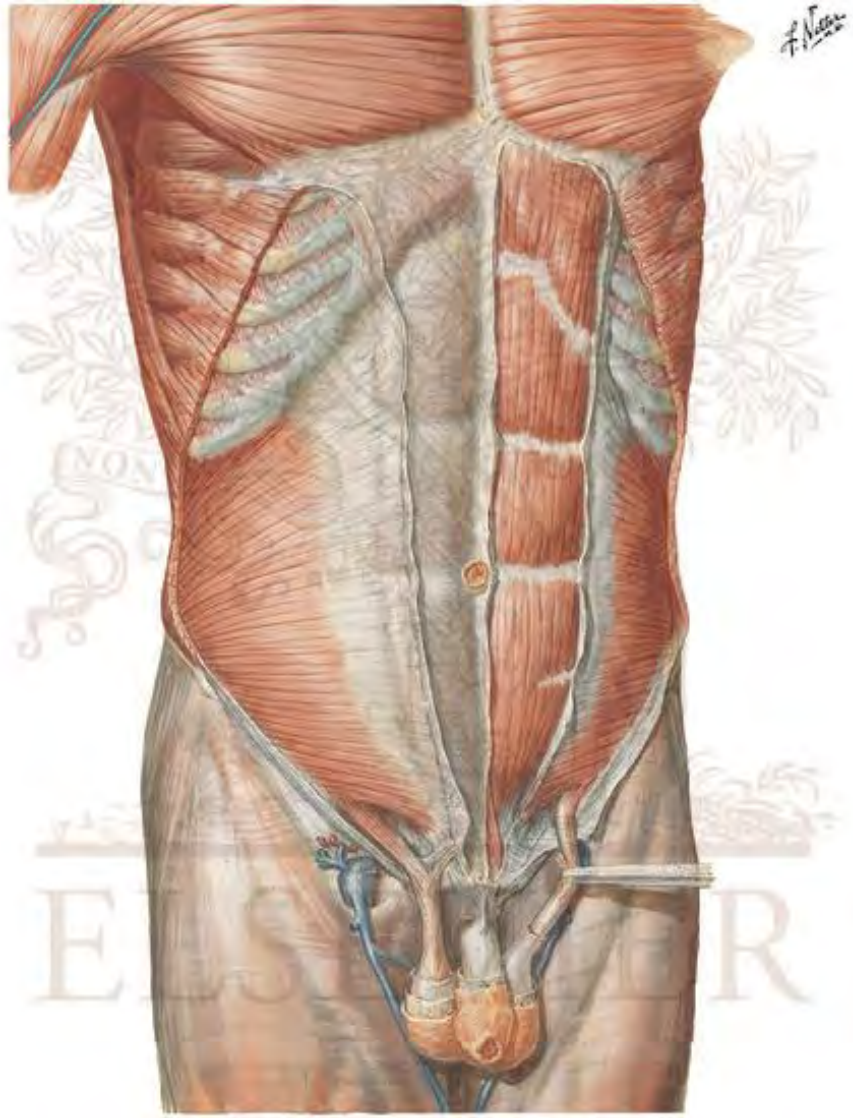

La natura è debole

Le debolezze della natura

La pericolosità dell’ernia

Sintomi:

Subocclusione intestinale ?
Dolore ?

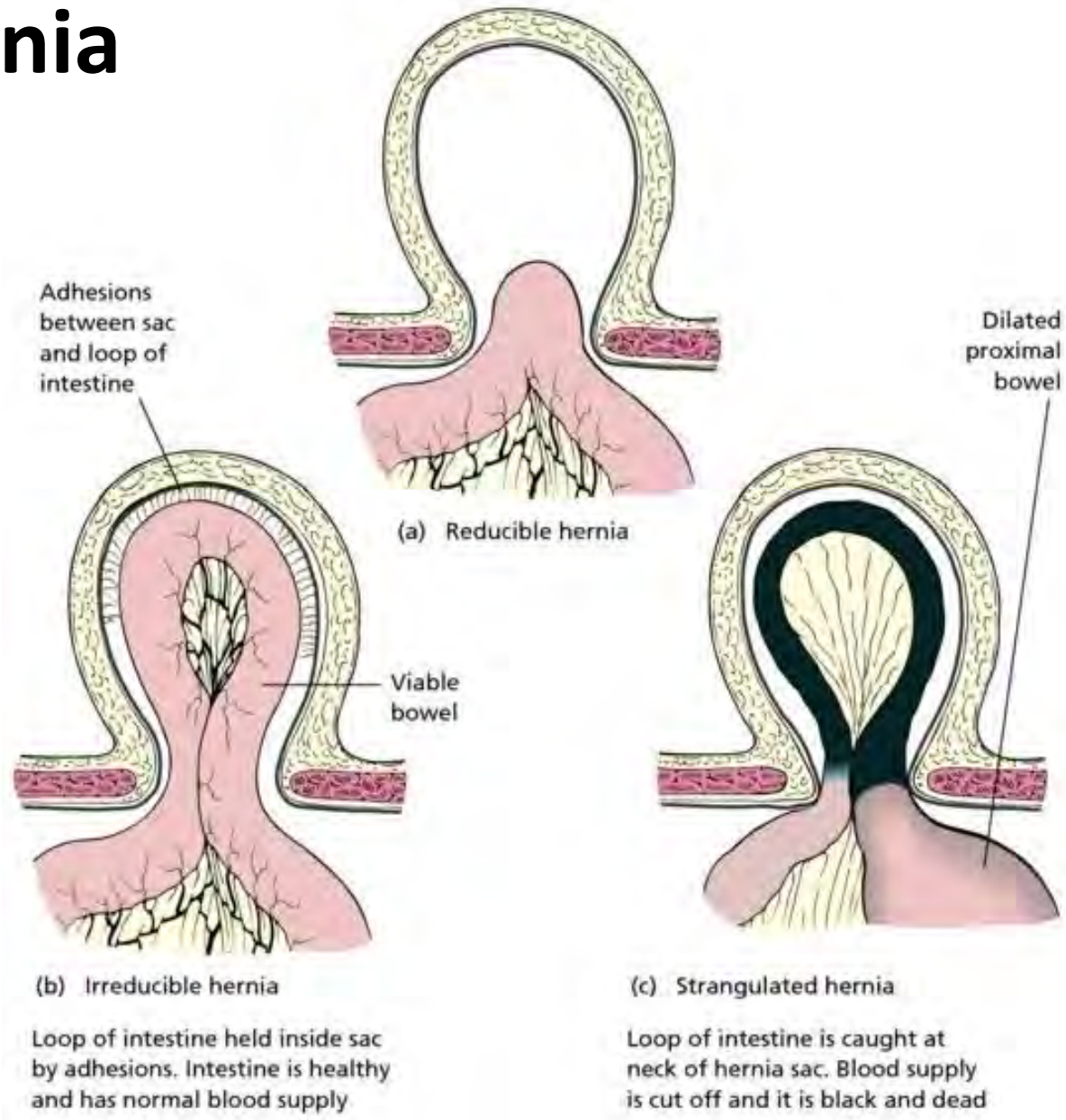

Ernie della parete addominale

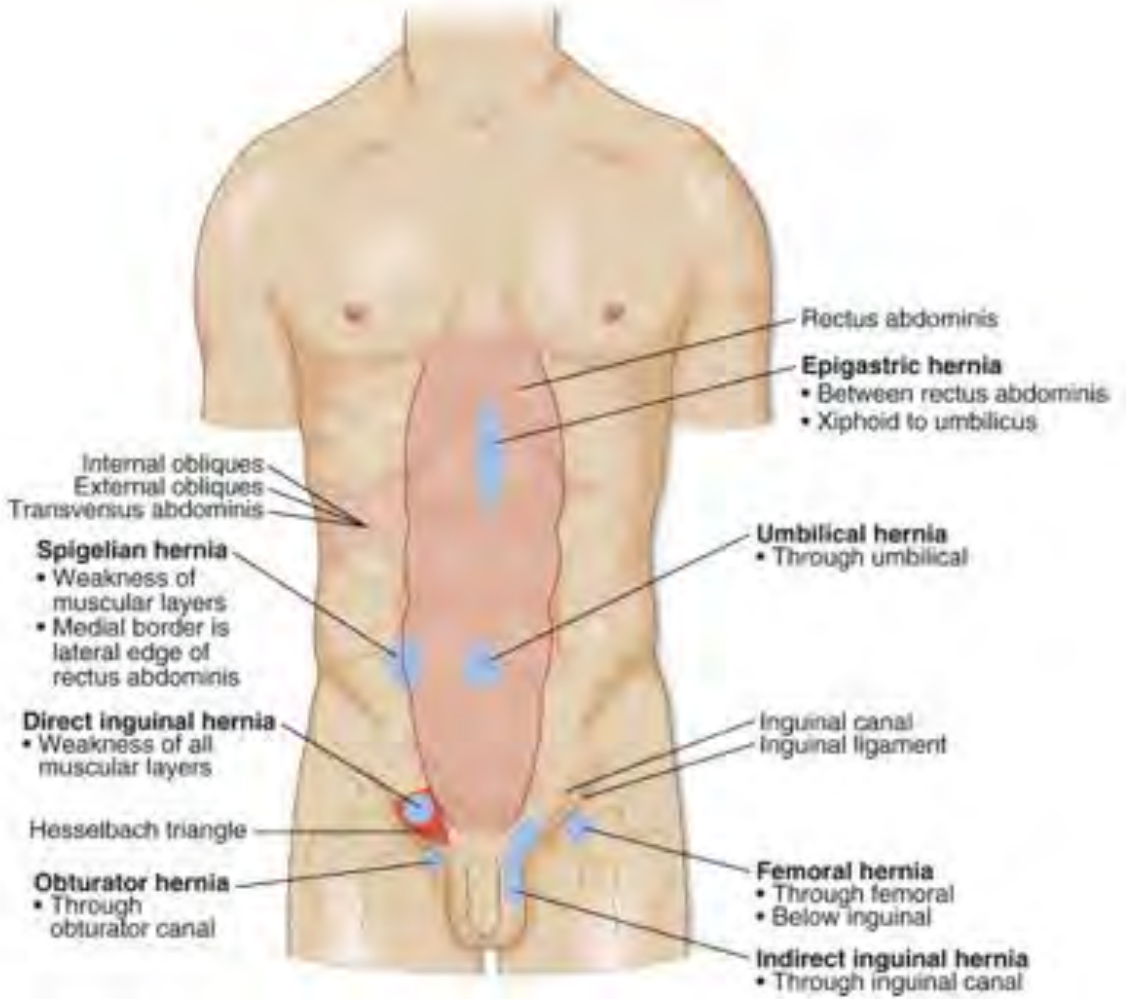

Localizzazione:

- **Inguinale (70.7%)**
  65% indiretta, 35% diretta
- **Ombelicale (13.9%)**
- **Epigastrica (6.6%)**
- **Incisionale (4.7%)**
- **Femorale (3.7%)**
- **Spigelio/altri (0.4%)**

JRSM Short Reports 2011

Ernie della parete addominale

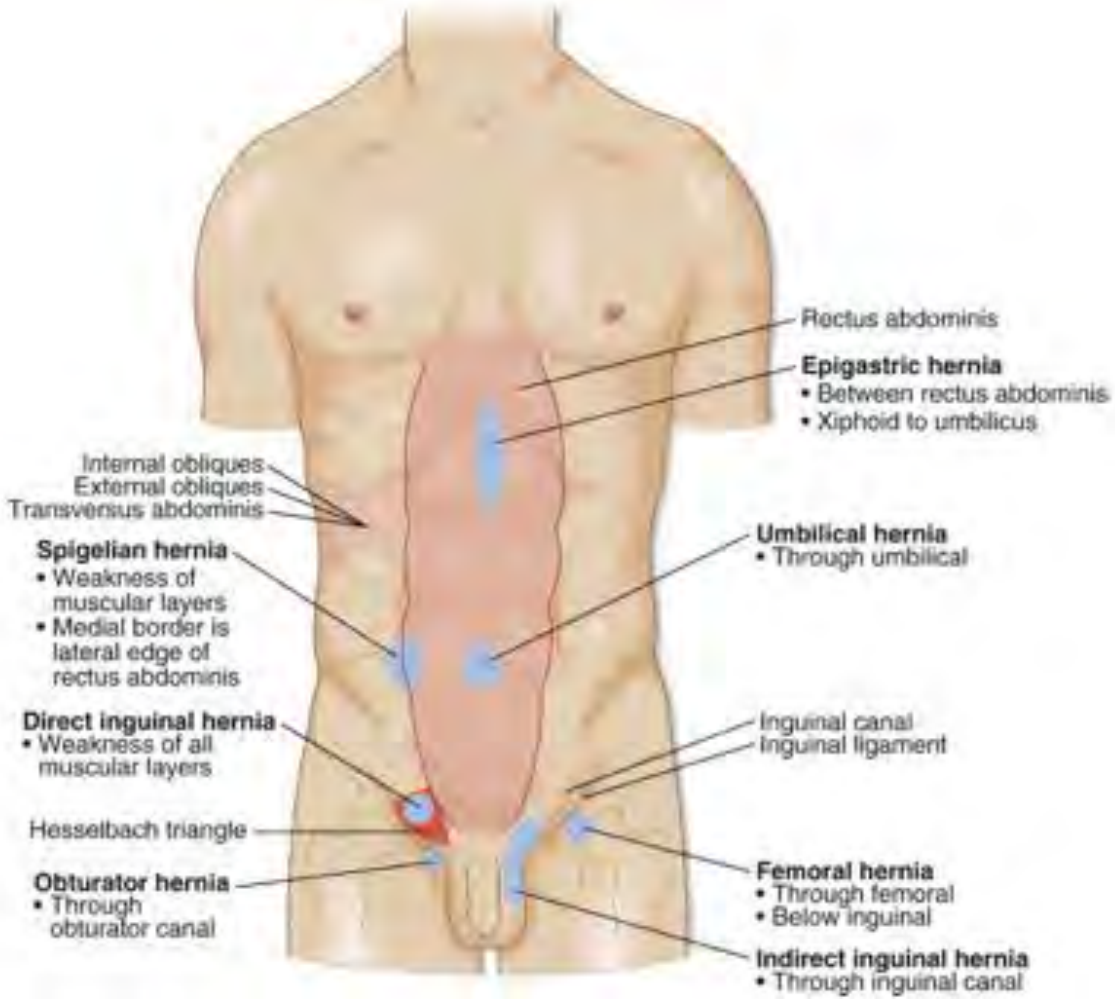

Insorgenza di ernie durante PD:

in circa 5% - 19%

- **Inguinale ca. 14% - 57%**
- **Ombelicale ca. 33% - 86%**
- **Combinata ca. 10%**

Int Urol Nephrol 2024 (pazienti europei),Ther Apher Dial 2023 (pazienti indiani)

Ernie della parete addominale

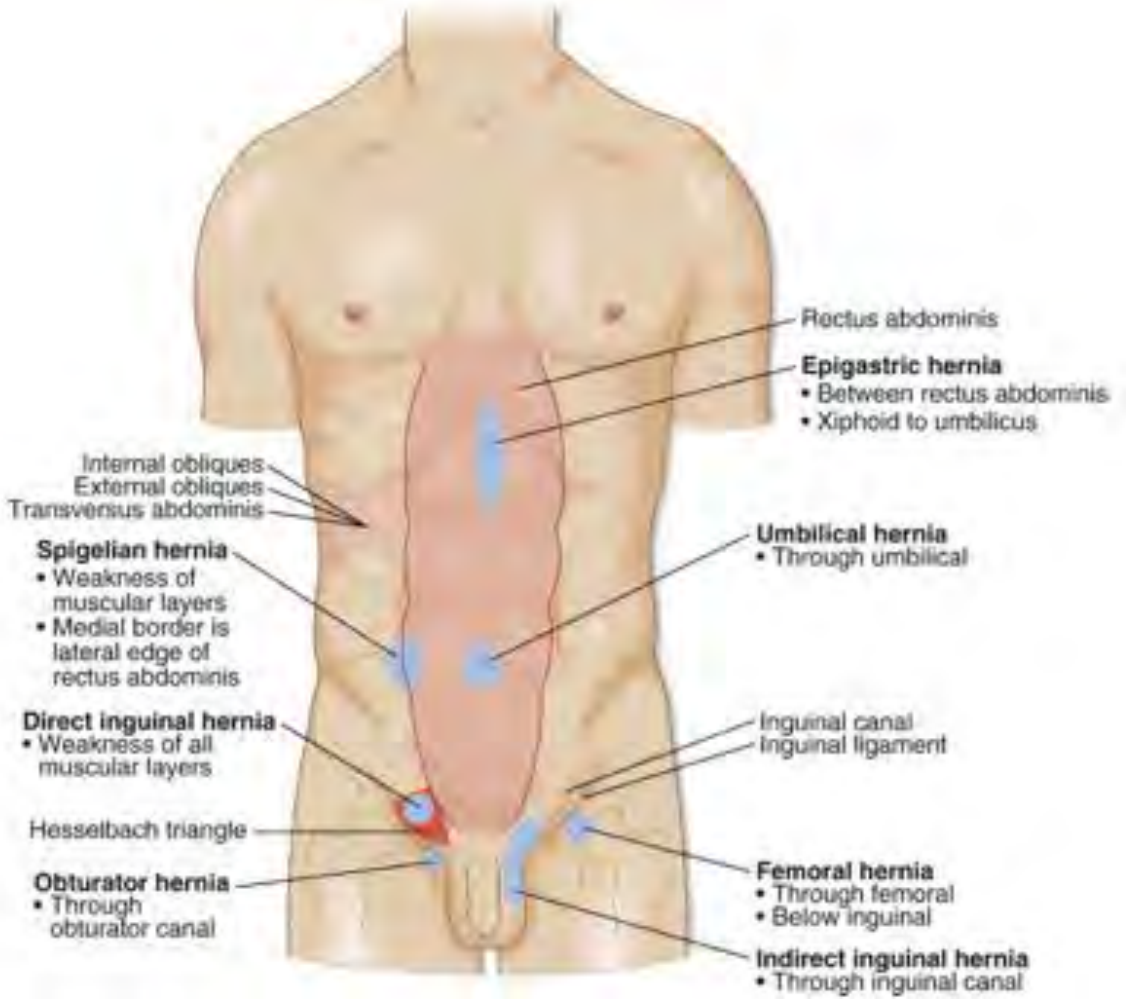

Fattori di rischio:

Sesso maschile
BMI elevato
Malattia policistica renale
Pressione intraperitoneale elevata
Longterm-PD, età elevata
CAPD>APD
Interventi chirurgici precedenti

Int Urol Nephrol 2024, Ther Apher Dial 2023, JRSM Short Reports 2011, Br J Surg 1997

La pressione intraperitoneale

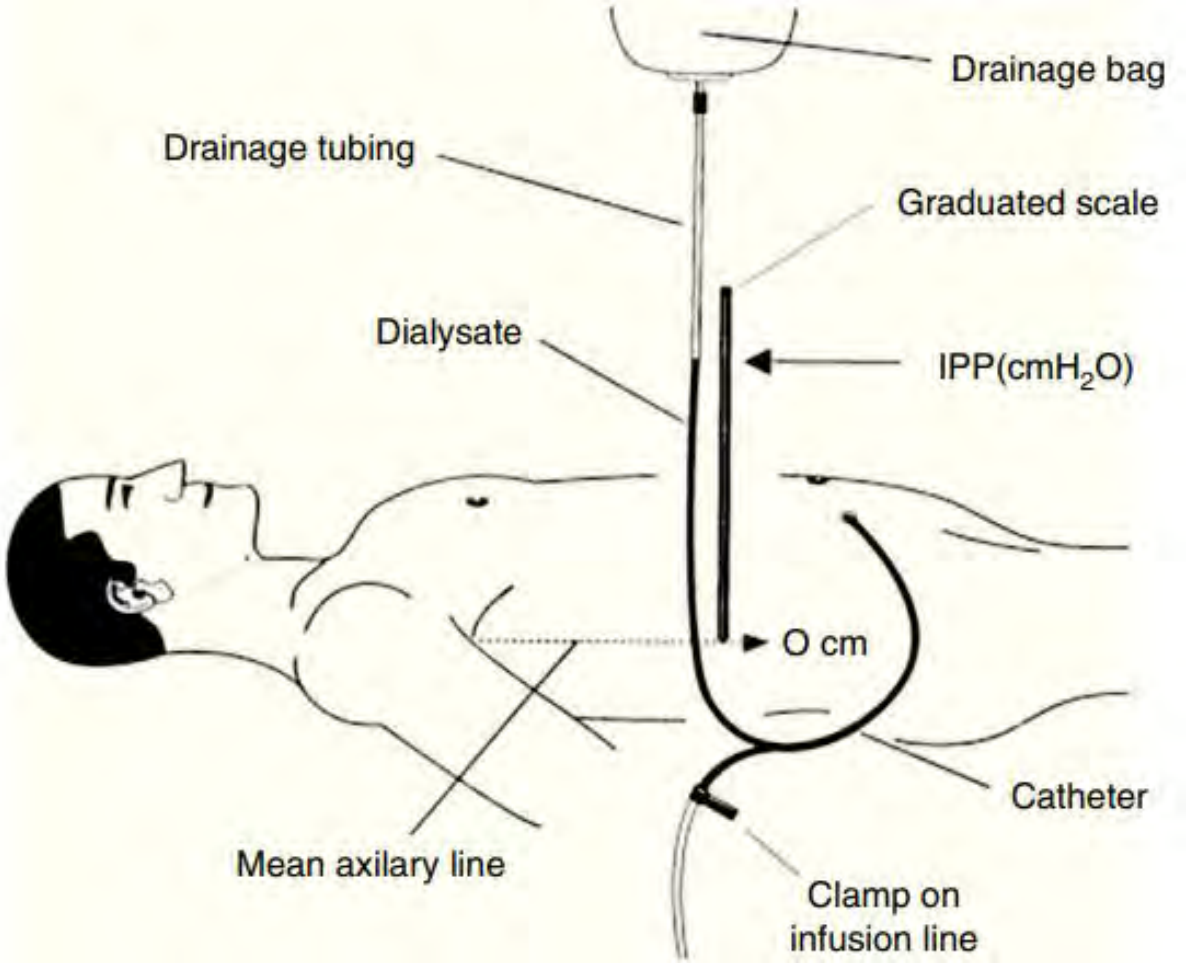

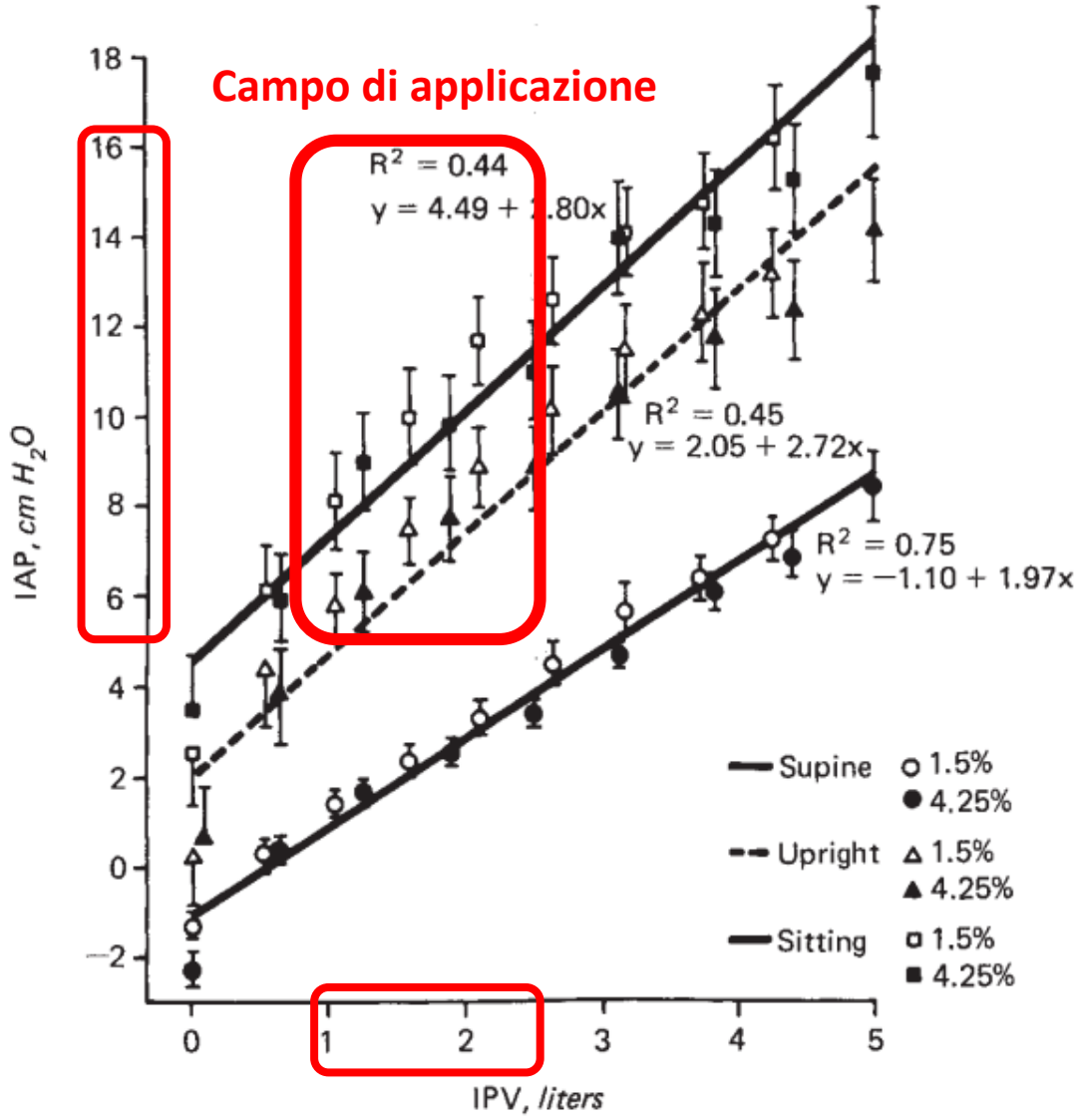

Intra-abdominal pressure (IAP) *related to calculated intraperitoneal volume* (IPV) *of 1.5 and 4.25% glucose solutions*. Means ± SEM. Linear regressions are also shown.

Adv Perit Dial 1994

Kidney Int 1983

La pressione intraperitoneale

1 mm Hg =
13 cm H_2O

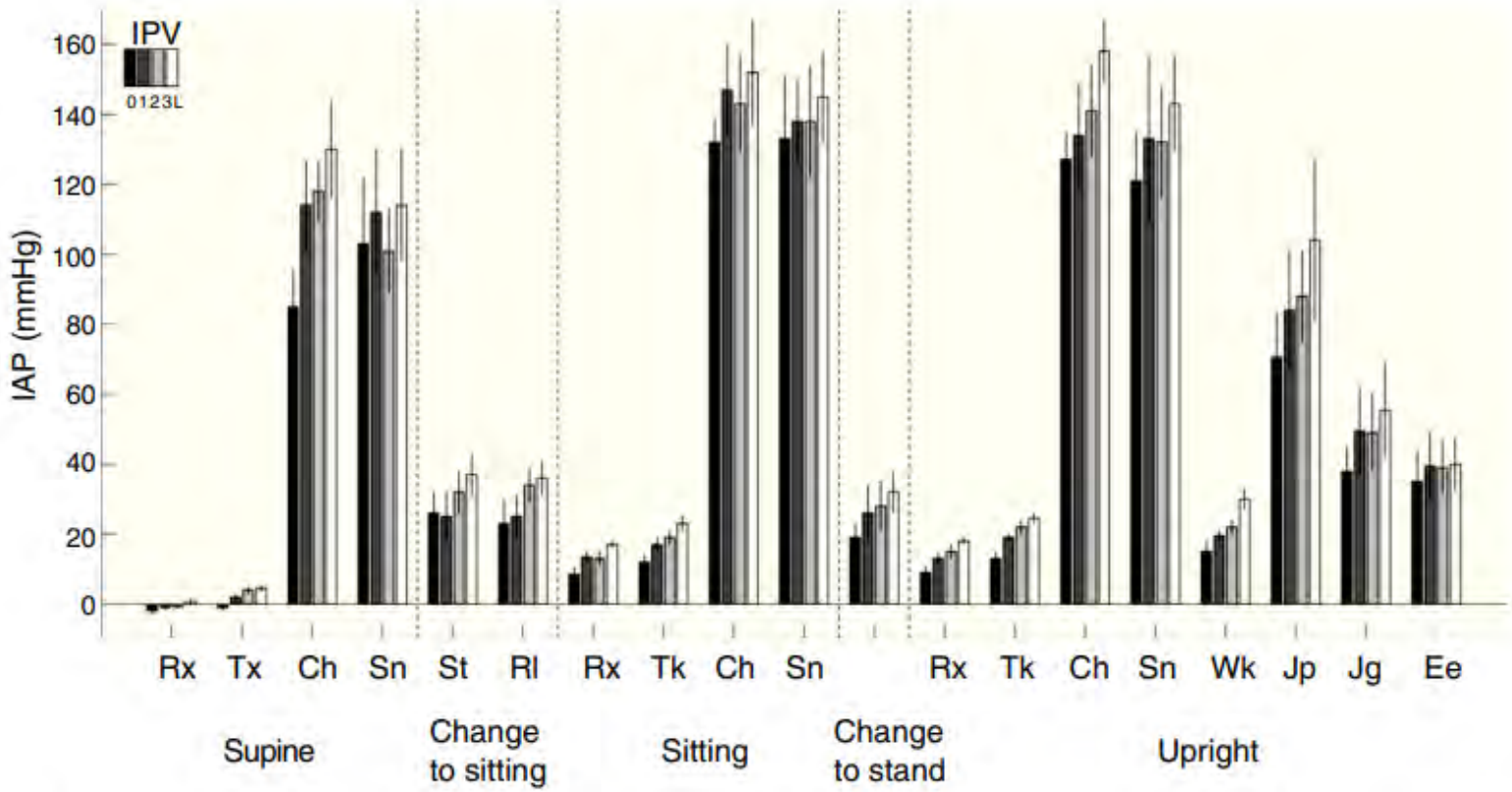

Intraperitoneal pressure (IPP) during natural activities with different intraperitoneal volumes (IPV) (0, 1, 2 and 3 L) in 6 patients. Note the large difference of basal values at rest, on the left, with all the others.
Rx: rest; Tx: talking; Ch: coughing; Sn: stretching; St: sitting up; Rl: rotating; Tk: talking: Wk: walking; Jp: jumping; Jg: jogging; Ee: on a static bicycle.

Nephron 1986, Nefrologia 2017

Nephrol Dial Transplant (2007) 22: 1437–1444
doi:10.1093/ndt/gfl745
Advance Access publication 17 February 2007

Original Article

NDT
Nephrology Dialysis Transplantation

Intraperitoneal pressure in PD patients: relationship to intraperitoneal volume, body size and PD-related complications

Agnès Dejardin[1], Annie Robert[2] and Eric Goffin[1]

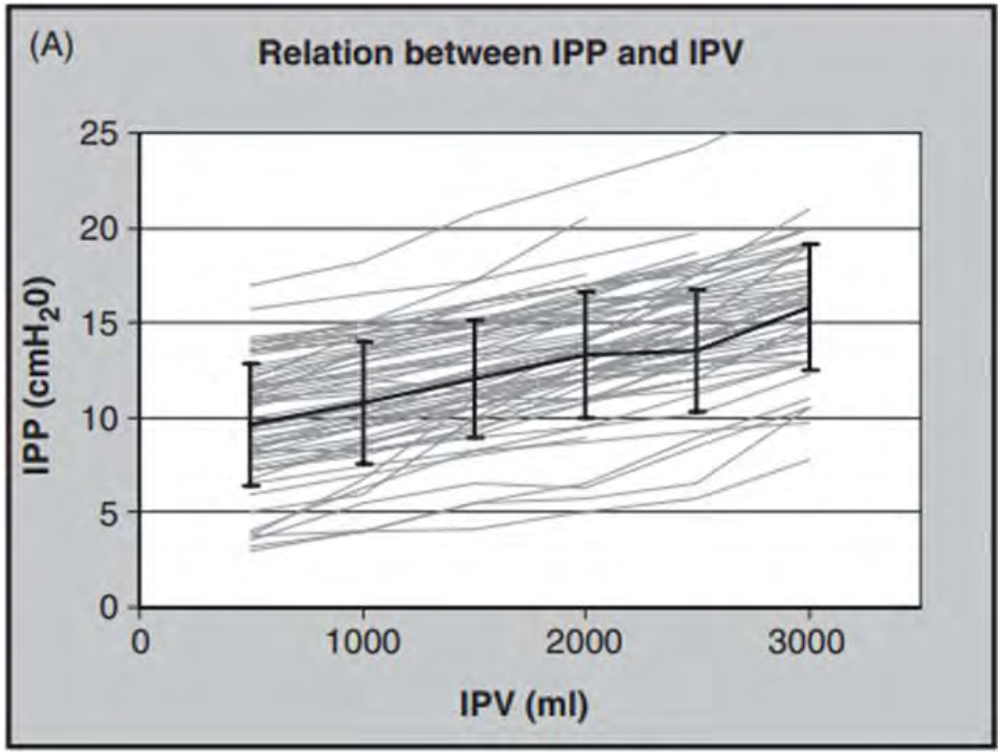

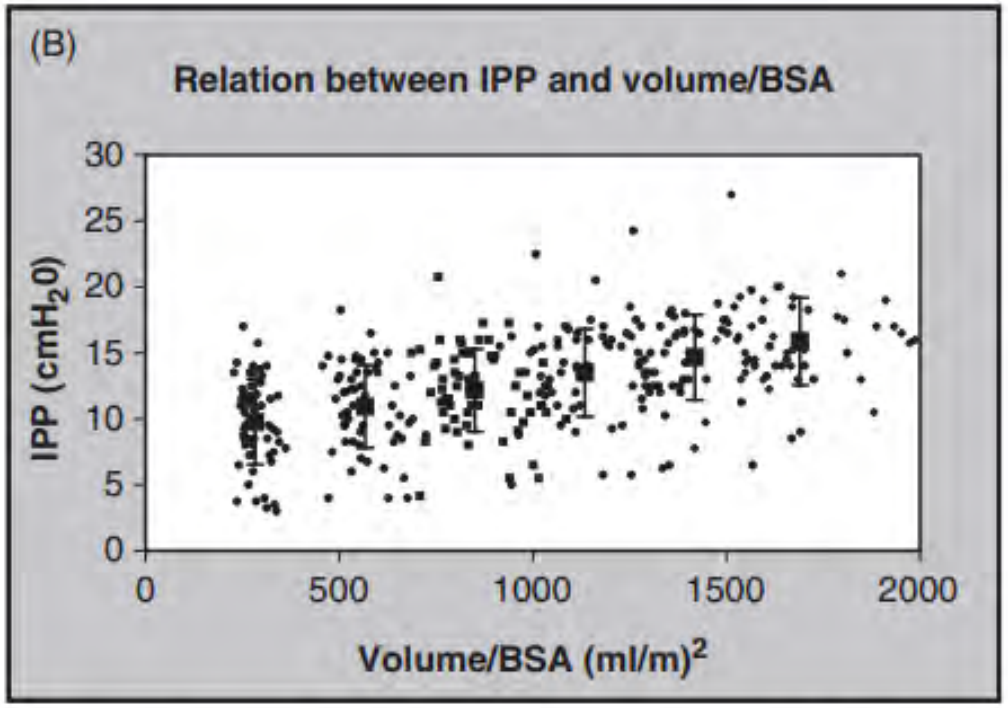

Relationship between IPP and IPV (A) and between IPP and IPV/BSA (B) in the whole population. Mean IPP for an inflow volume of 0ml was 8.8 ± 3.3 (range 0.5–15.8) cm H_2O whereas mean IPP for an inflow volume of 2000 ml was 13.5 ± 3.3 (range 5.0 to 22.5) cm H_2O. IPP increased linearly by 1.3 ± 0.4 cm H_2O for each additional 500 ml infused, independently of IPP of the empty cavity. Mean coefficient correlation was 0.96 ± 0.04.

Nephrol Dial Transplant 2007

KI REPORTS
KIReports.org
CLINICAL RESEARCH

Identification of the Factors Associated With Intraperitoneal Pressure in ADPKD Patients Treated With Peritoneal Dialysis

Check for updates

Mickael Sigogne[1,2,3], Lukshe Kanagaratnam[4], Caroline Mora[1], Malika Pierre[1], Andreea Petrache[1], Claude Marcus[1], Michel Fischbach[5], Moustapha Dramé[2] and Fatouma Touré[1,6]

Table 3. Univariate analysis

Data	Estimated value β	R^2	*P*
Age	0.03	0.009	0.461
Body mass index	0.42	0.251	<0.0001
Height	5.73	0.024	0.2354
Sex	0.58	0.007	0.5279
Body surface area	5.86	0.148	0.0024
Pregnancy	−0.54	0.040	0.1239
Liver volume	0.0006	0.012	0.4064
Total kidney volume	0.0001	0.003	0.6562
Abdominal volume	0.0005	0.191	0.0005
IPV	0.0035	0.107	0.0108

IPV, volume of dialysate infused in the peritoneal cavity.
Factors are associated with intraperitoneal pressure.

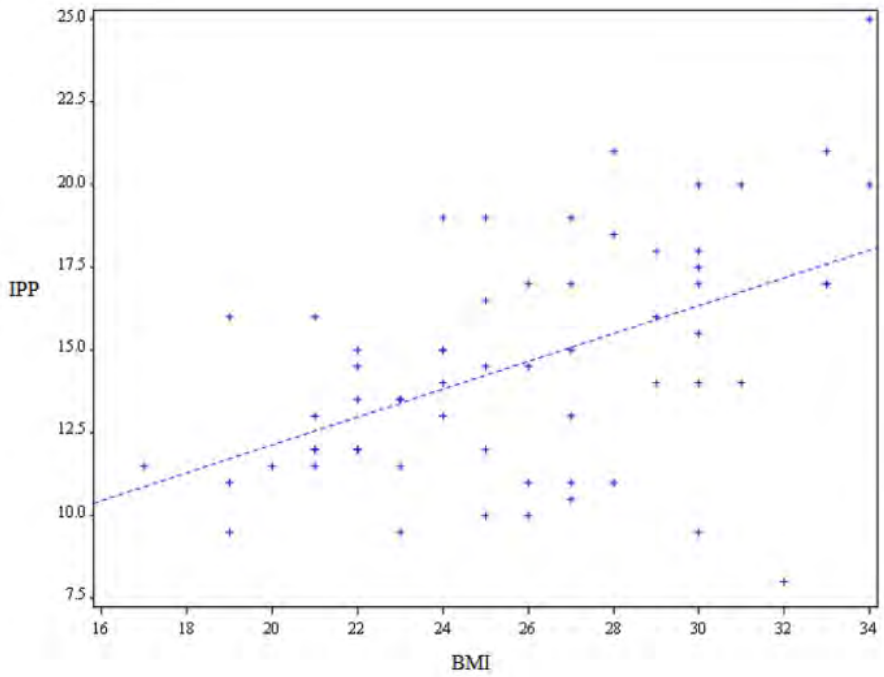

Table 4. Multivariate analysis of intraperitoneal pressure and clinical and radiological data

Data	Estimated value β	*P*
Body mass index	0.372	0.0004
IPV	0.002	0.1043

IPV, volume of dialysate infused in the peritoneal cavity.

Kidney Int Rep 2020

Intraperitoneal Pressure Has a Prognostic Impact on Peritoneal Dialysis Patients

Mean Intraperitoneal Pressure (IPP) in the Presence of Complications

Complication	Present Mean IPP (cmH_2O)	Present Pts (n)	Absent Mean IPP (cmH_2O)	Absent Pts (n)	p Value
Abdominal wall hernia	21.1±5.8	11	18.2±5.0	43	0.097
Hydrothorax	18.5±6.5	3	18.8±5.2	51	0.931
Gastroesophageal reflux	16.0±3.4	4	19.0±5.3	50	0.271
TOTAL	19.8±5.6	17	18.3±5.0	37	0.321

Pts = patients.

Perit Dial Int 2014

Tipi di Ernie inguinali

Hernia type	Other names	Location of the hernia defect
Lateral inguinal hernia	Indirect, oblique	Lateral to the inferior epigastric vessels, above the inguinal ligament, through the lateral inguinal fossa
Medial inguinal hernia	Direct	Medial to the inferior epigastric vessels, above the inguinal ligament, through the medial fossa (the Hesselbach's triangle)
Femoral hernia	Typical femoral hernia	through the femoral canal, below the inguinal ligament, in the lacuna vasorum, between the vena femoralis and the ligamentum lacunare
Prevascular femoral hernia	Velpeau, Narath, Teale	below the inguinal ligament, in the lacuna vasorum, in front of the femoral vessels
Retrovascular femoral hernia	Serafini	below the inguinal ligament, in the lacuna vasorum, immediately posterior to the femoral vessels
Lateral anterior femoral hernia	Hesselbach	through the lacuna musculorum anteriorly
Lateral posterior femoral hernia	Partridge	through the lacuna musculorum posteriorly
Pectineal hernia	Cloquet, Callisen-Cloquet	through the pectineal fascia
Lacunar hernia	Laugier, Gimbernant	through an opening in the lacunar ligament
Obturator hernia		through the obturator canal

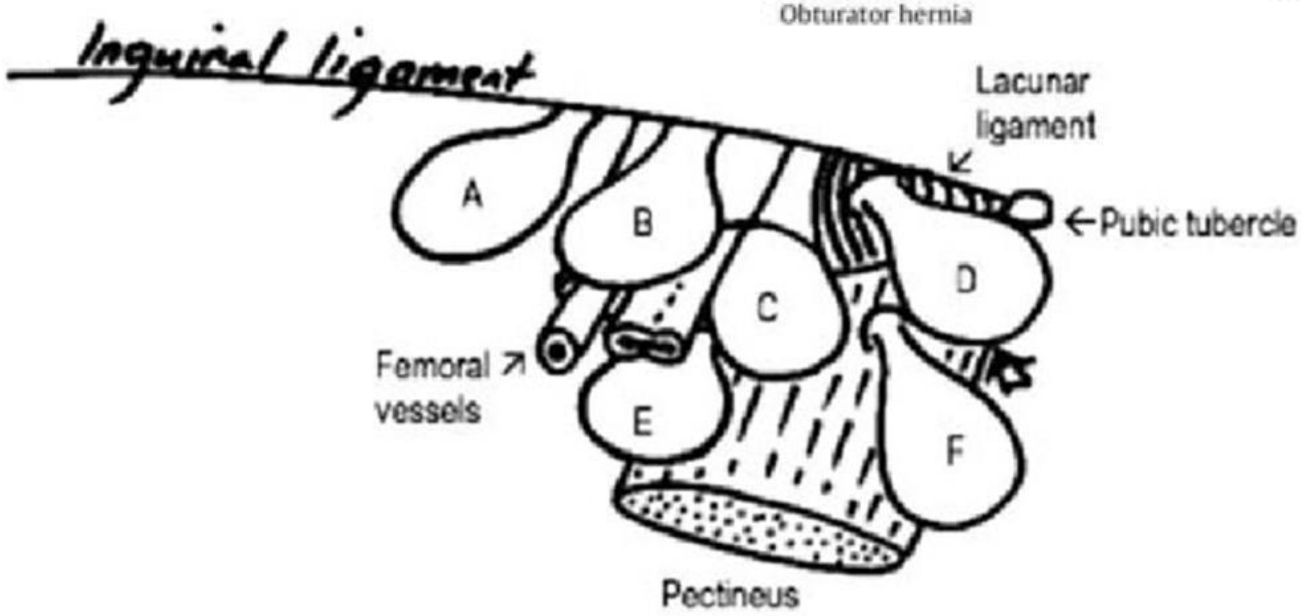

Schematic view of right femoral region

A	**Hesselbach**
B	**Velpeau**
C	**Femoral**
D	**Laugier**
E	**Serafini**
F	**Cloquet**

International Journal of Surgery Case Reports 2016

Tipi di Ernie inguinali

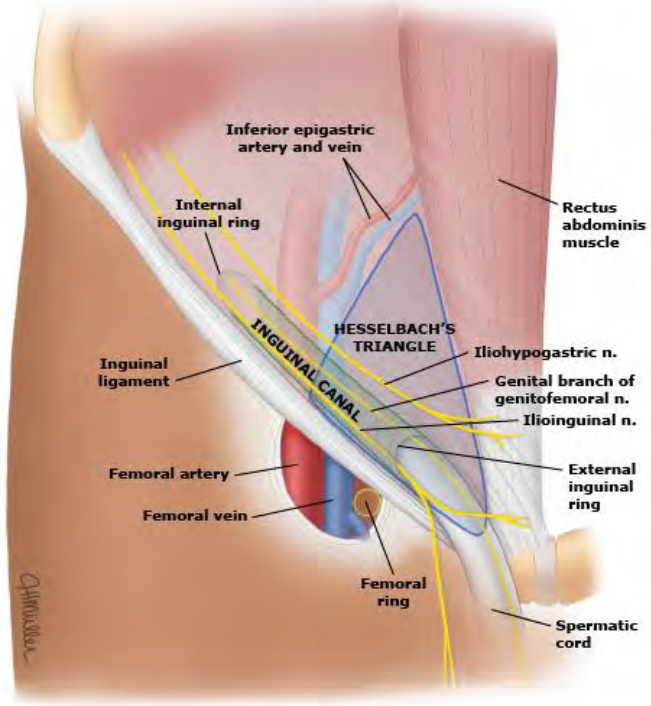

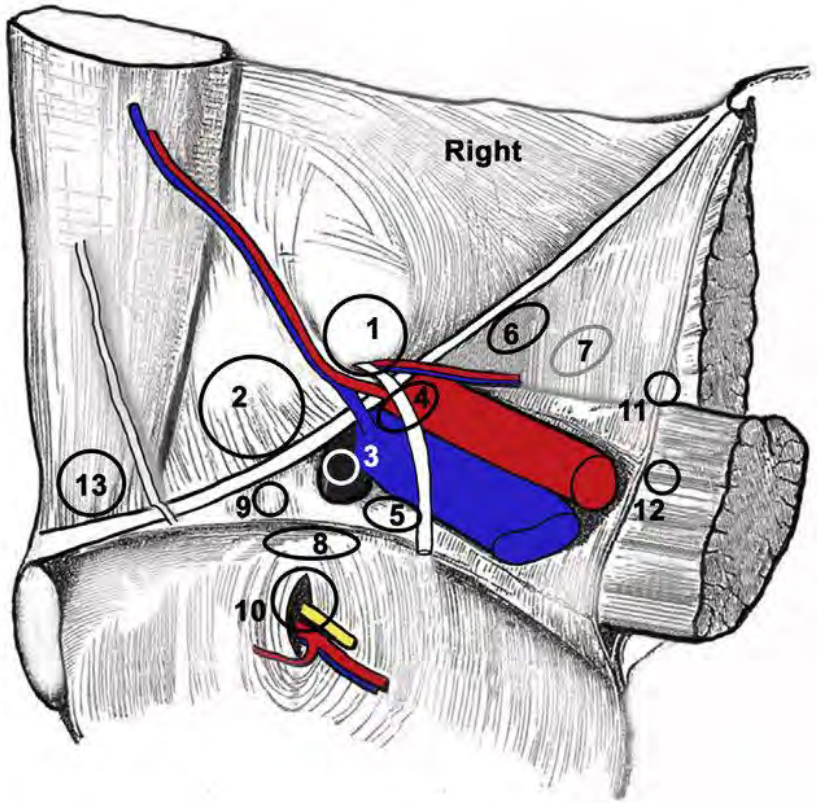

1 - Lateral inguinal hernia, **2** - Medial inguinal hernia,
3 - Femoral hernia, **4** - Prevascular femoral hernia,
5 - Retrovascular femoral hernia, **6** - Lateral anterior femoral hernia,
7 - Lateral posterior femoral hernia, **8** - Pectineal hernia,
9 - Lacunar hernia, **10** - Obturator hernia, **11** - Retropsoas hernia,
12 - Psoas hernia, **13** - Supravesical hernia

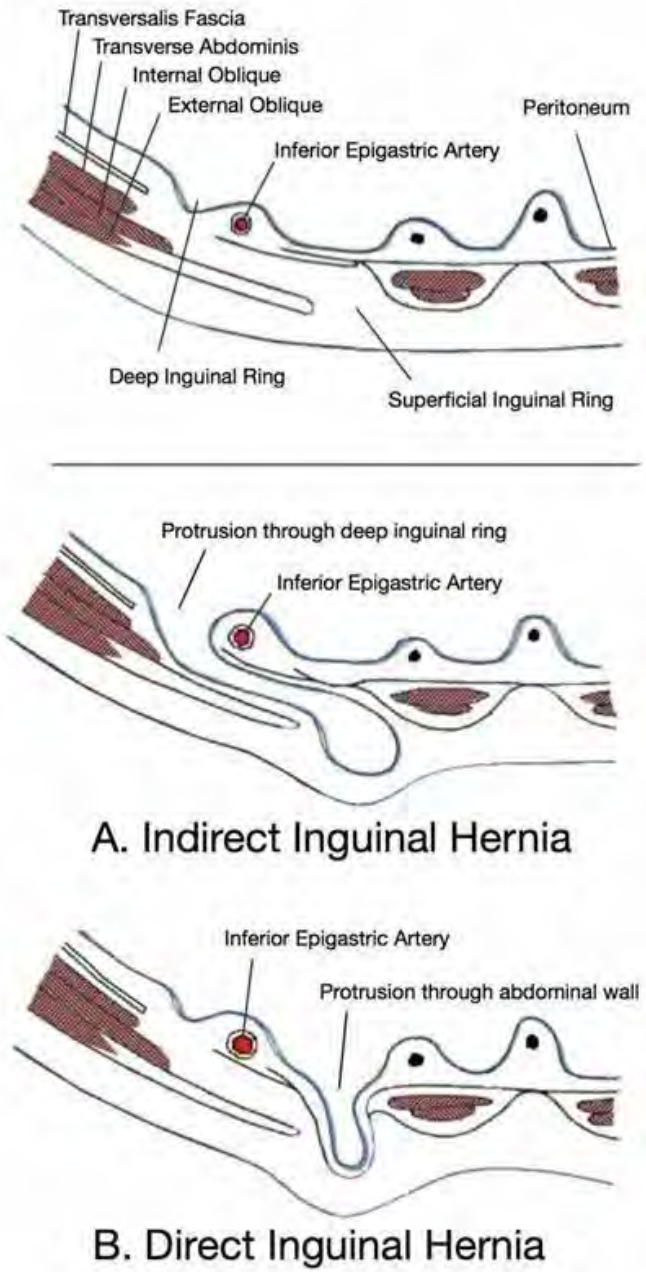

Ernie inguinali

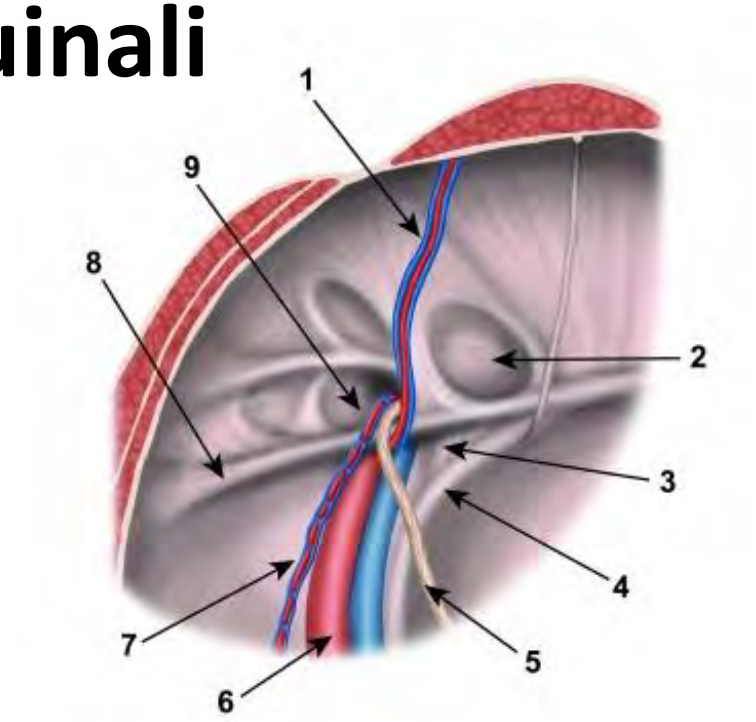

Posterior aspect of the inguinal region:

1 - Inferior epigastric artery and vein
2 - Medial orifice - direct inguinal hernia
3 - Femoral hernia orifice
4 - Pectineal ligament (Cooper)
5 - Spermatic duct
6 - External iliac artery and vein
7 - Testicular artery and vein
8 - Iliopubic tract
9 - Lateral orifice - indirect inguinal hernia

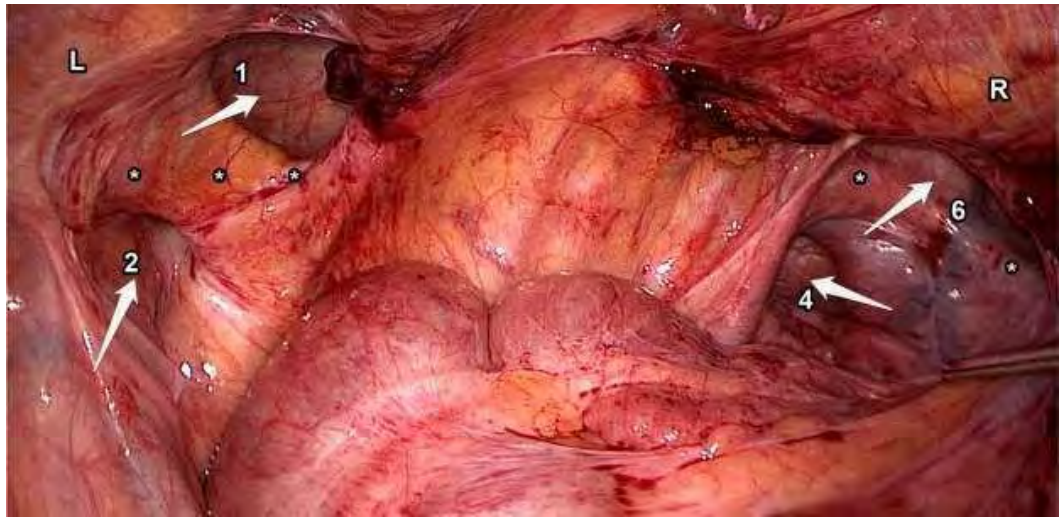

Intraperitoneal inspection during laparoscopy:

***** - The inguinal ligament
L - Left, **R** - Right
1 - Medial inguinal hernia – direct ingiunal hernia
2 - Left prevascular femoral hernia
4 - Right prevascular femoral hernia
6 - Lateral inguinal hernia – indirect inguinal hernia

International Journal of Surgery Case Reports 2016

Difetti del diaframma - Idrotorace

Potential diaphragmatic defects/hernias:

1 - Morgagni's
2 - Larrey's
3 - Peritoneopericardial communication
(defect of the septum transversum)
4 - Paracaval hernia
5 - Hiatal hernia
6 - Pleuroperitoneal
7 - Bochdalek's (lumbocostal triangle/ trigone)
Arrows - direction of potential extension

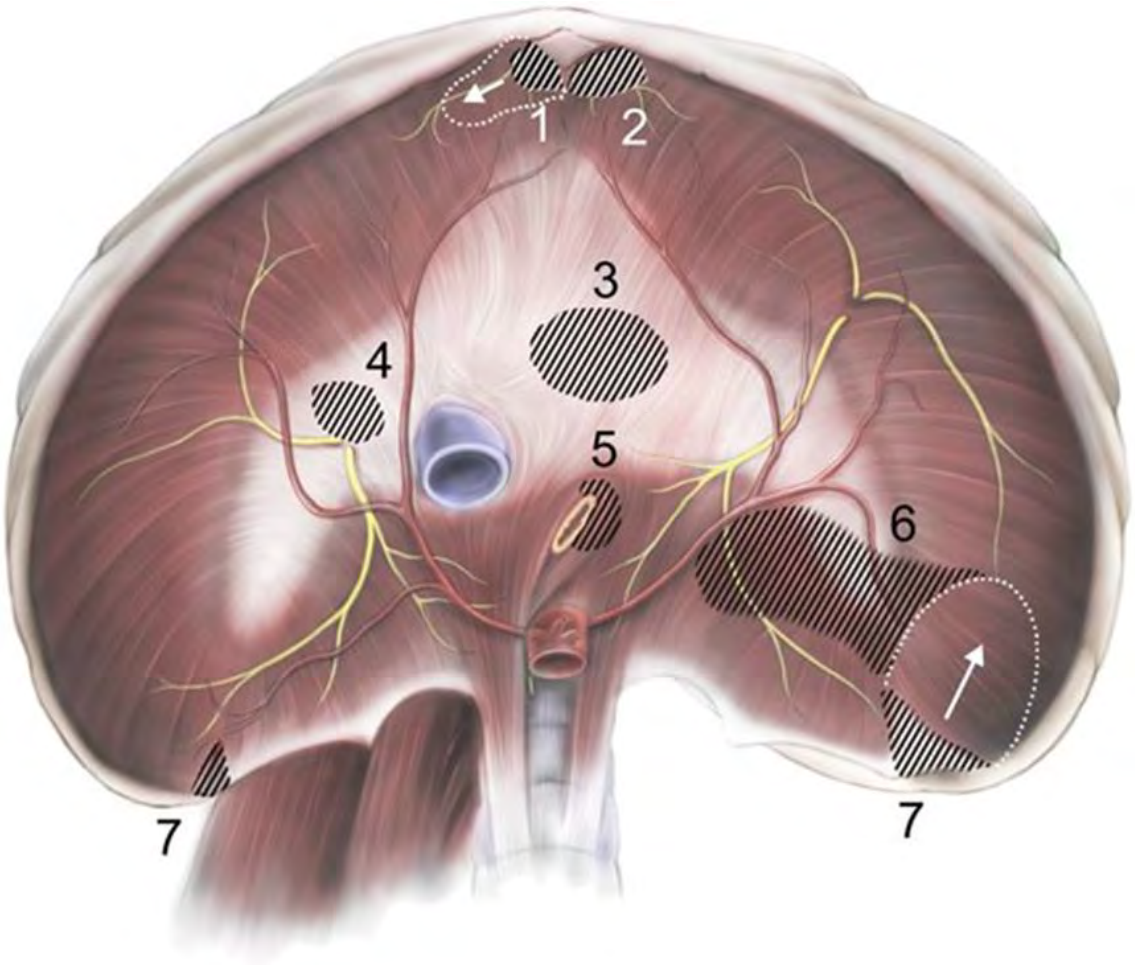

Incidenza ca 1% - 7%, destro in ca. 88%
femmina > maschio
asintomatico in 25%
malattia policistica renale

Leakage

Fuoriuscita di liquido dialitico dalla cavità peritoneale nei tessuti circonstanti

- in assenza di membrana o

- presenza di rottura della membrana (peritoneale)

Prevalenza fino a 10%

Early leakage (entro 30gg) in 66%

fattori di rischio: intervento chirurgico
pressione intraperitoneale
early / urgent start PD
steroidi, sirolimus

Late leakage

Fattori di rischio: pressione intraperitoneale
età >65aa
obesità
APKD
gravidanze multiple
esercizio fisico

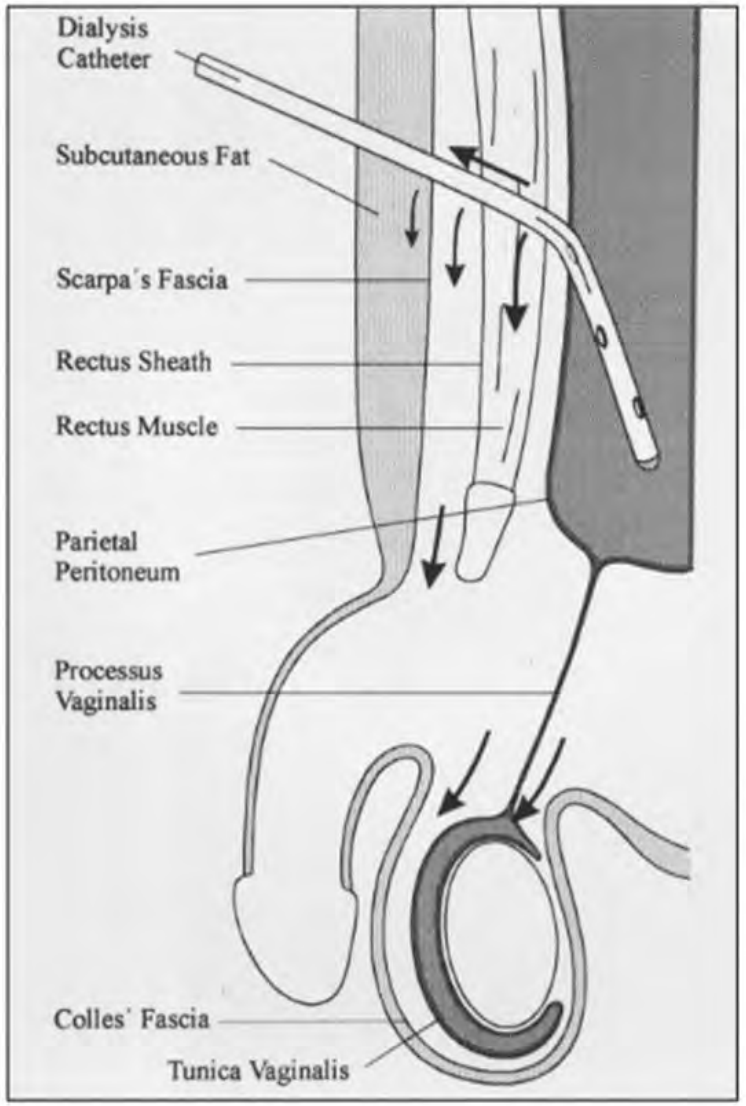

Fig. 4.—Drawing shows course of peritoneal dialysis catheter in abdominal wall. Note possible directions of fluid leaks (*arrows*). (Modified from and reprinted with permission of [12])

Am J Radiol 2000

Diagnostica

Diagnostica

Low cost
Eseguibile sotto sforzo
- Valsalva manovra
- Posizione eretta
- Addome riempito

Ernia – sacco/contenuto riponibile ?
Dolore – edema - eritema locale ?

Precisione per piccoli difetti della parete e zona inguinale

Eseguibile anche sotto sforzo

Esame con mezzo contrasto ecografico:
- specialmente per comunicazione peritoneo-pleurica
- leakage

Diagnostica – Ecografia

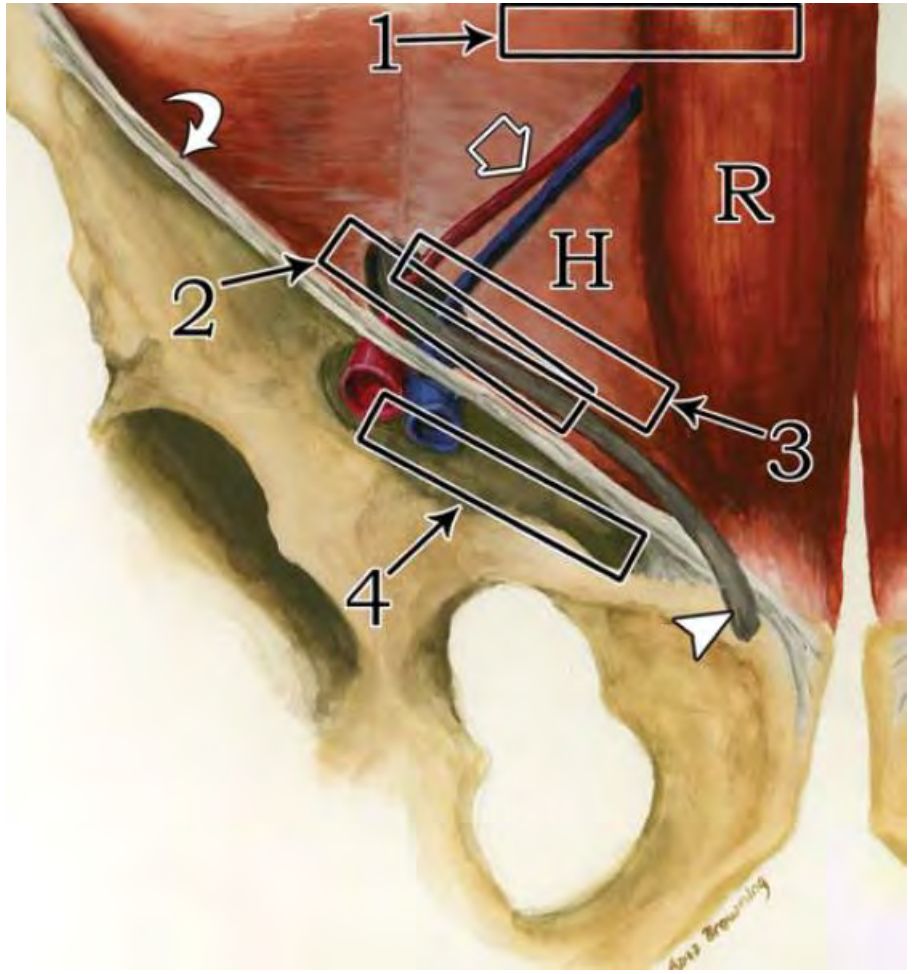

Man's right inguinal region from anterior view:
Ultrasound transducer position to evaluate
1 - spigelian hernia
2 - indirect inguinal hernia
3 - direct inguinal hernia
4 - femoral hernia

Curved arrow - inguinal ligament
R - rectus abdominis muscle
H - lateral boundary of Hesselbach's triangle defined by inferior epigastric artery (*open arrow*), and spermatic cord (*arrowhead*).

Diagnostica – Ecografia

Ernia inguinale con atti di respiro

Diagnostica – Ecografia

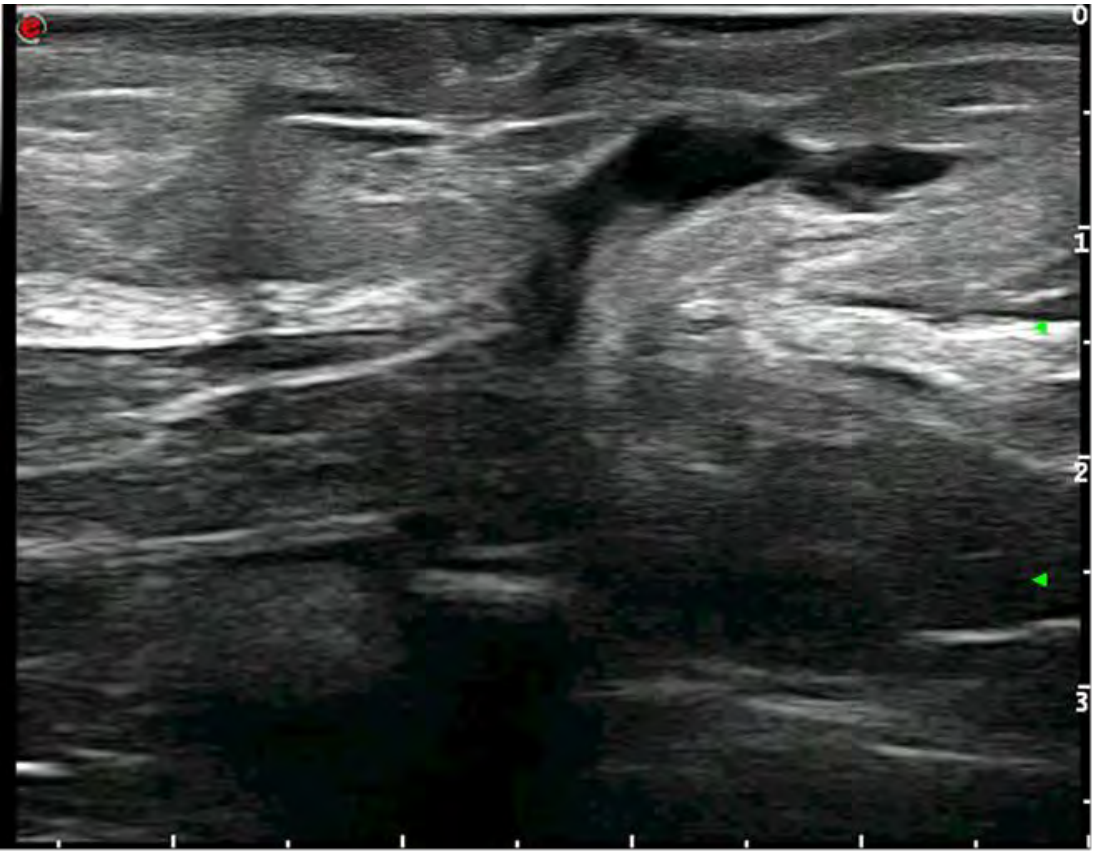

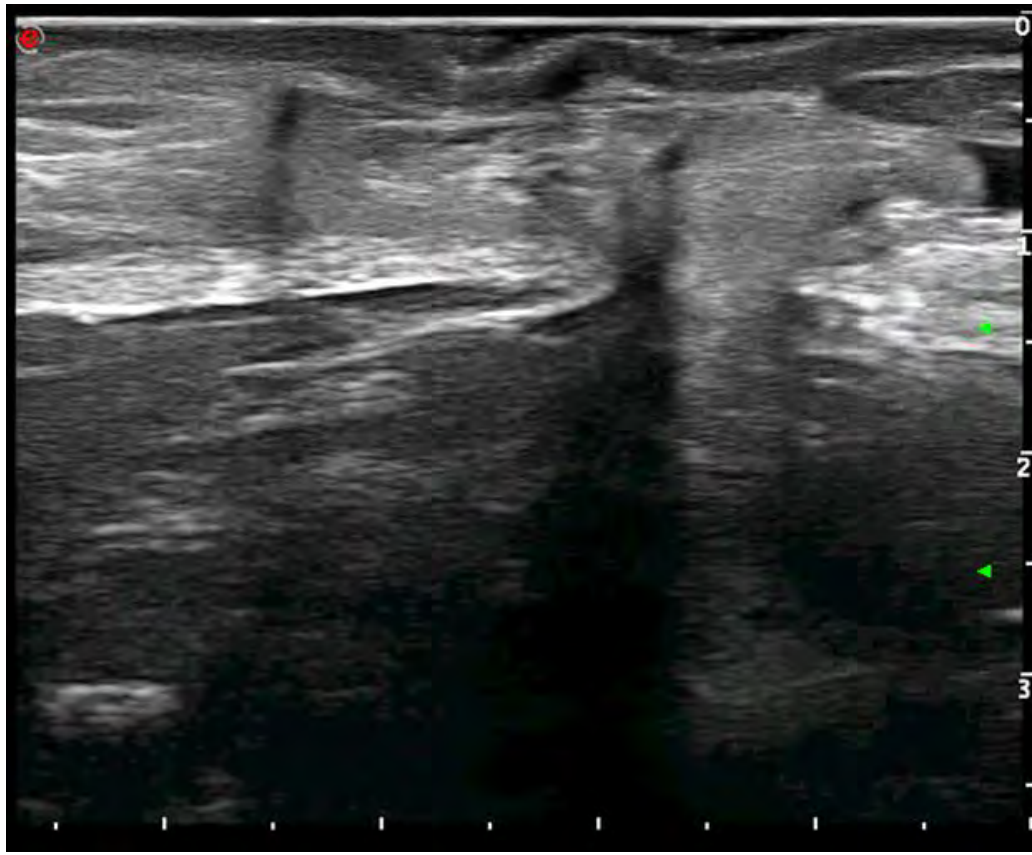

Valsalva Manovra

Diagnostica – Ecografia

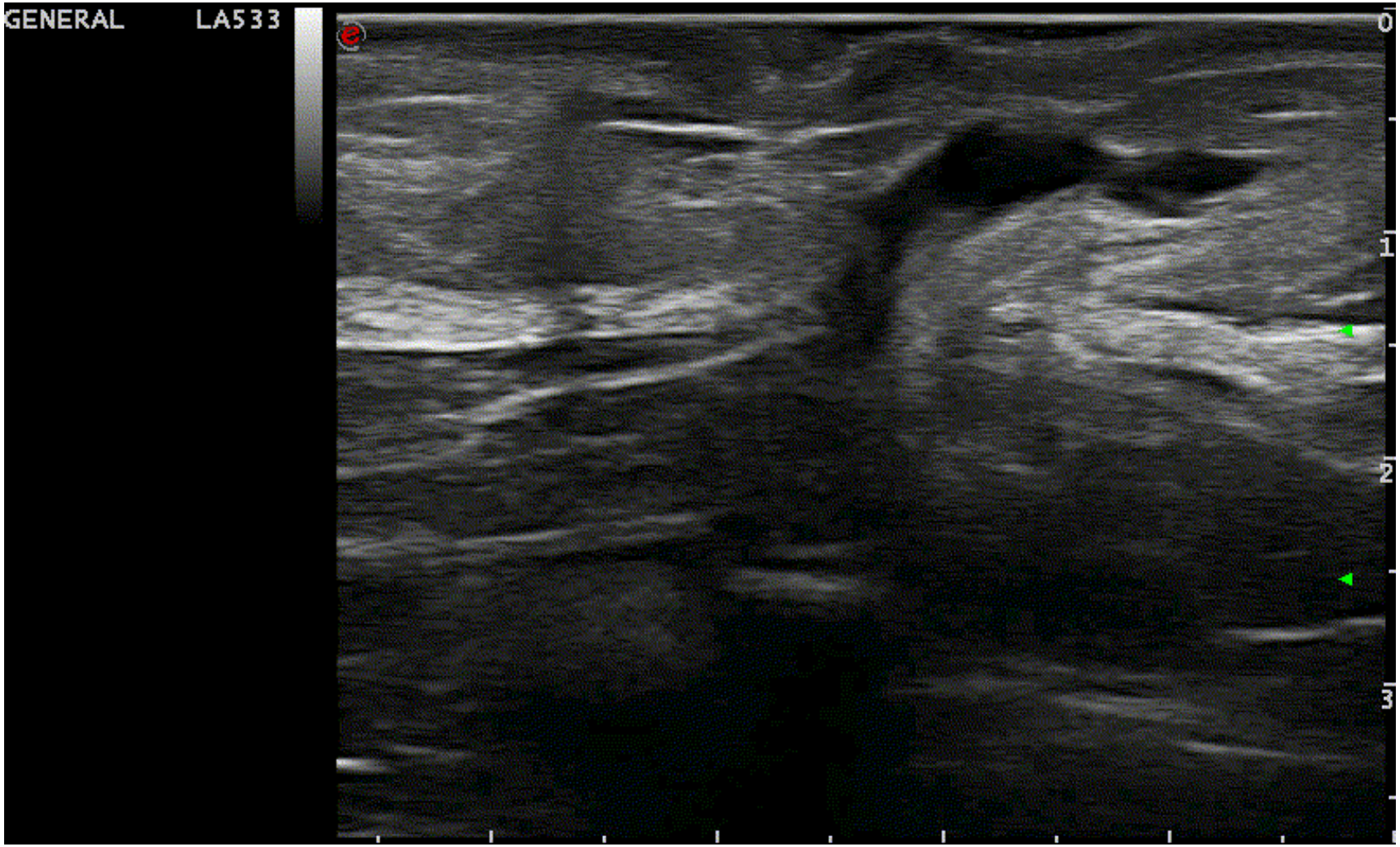

Valsalva Manovra

Diagnostica – Ecografia

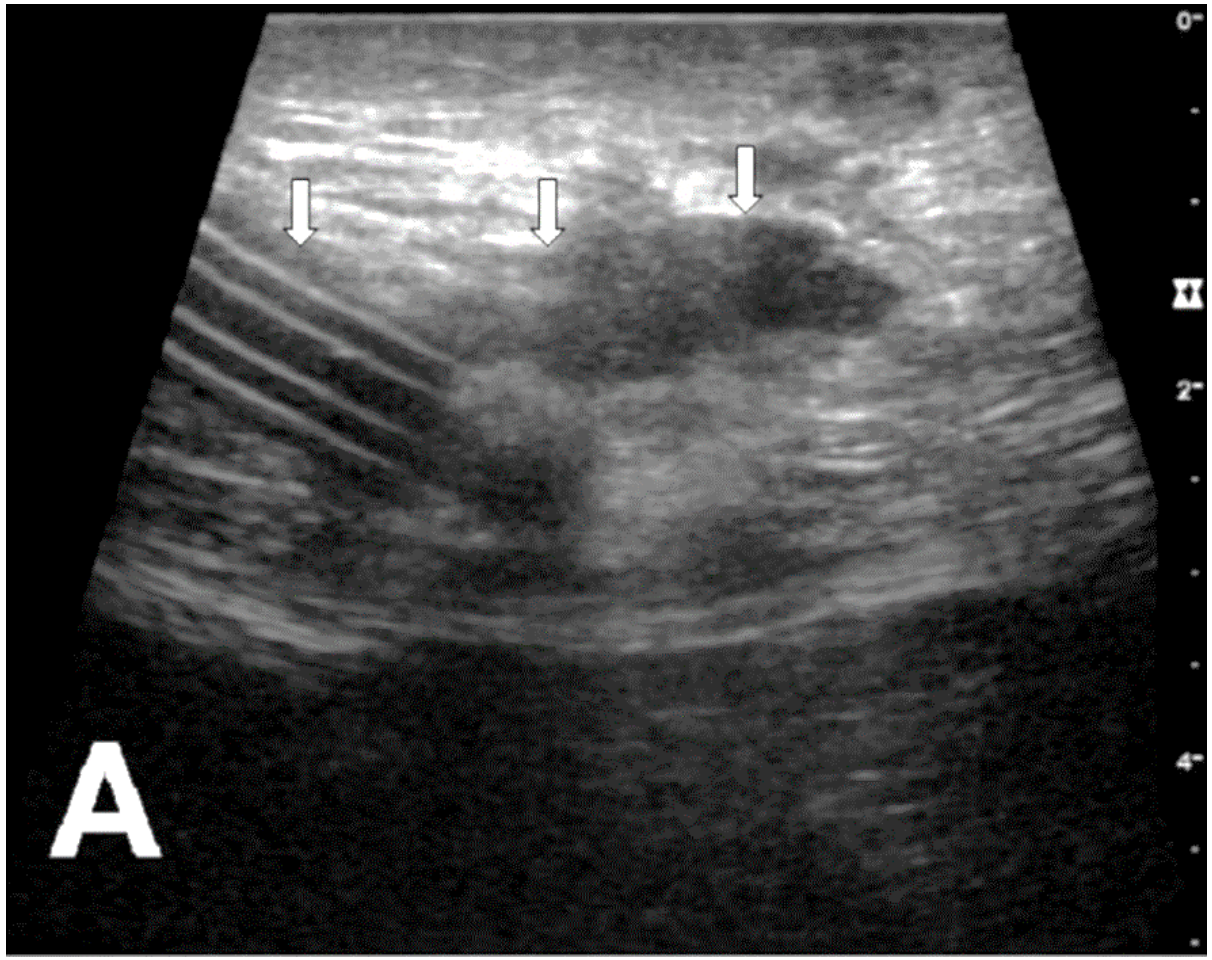

Leakage:
riscontro prevalente
nel periodo post-operatorio

In Ecografia:
Raccolta ipoecogena
Senza ipervascolarizzazione

A - Leakage alla cuffia interna e lungo il catetere peritoneale

J Ultrasound Med 2021, Granata & Zeiler

Diagnostica – Ecografia

Edema in zona addome infero-laterale

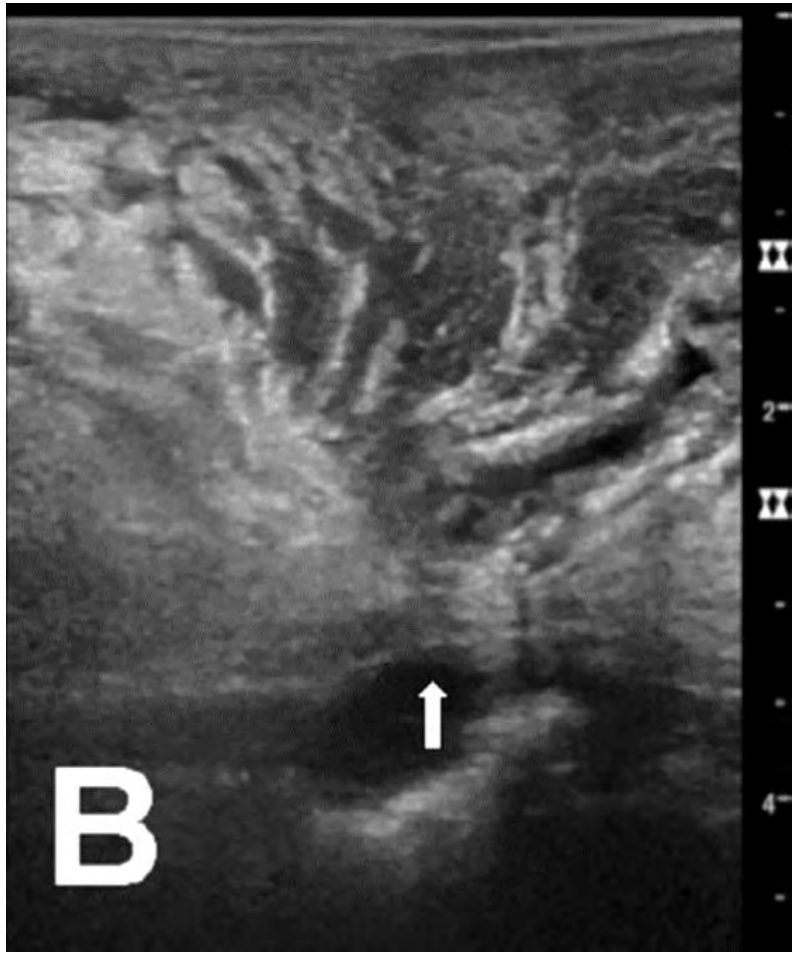

B – Leakage da difetto ombelicale

J Ultrasound Med 2021, Granata & Zeiler

Diagnostica – Ecografia - CEUS

Contrast-enhanced ultrasound in peritoneal dialysis: When and how to perform it.

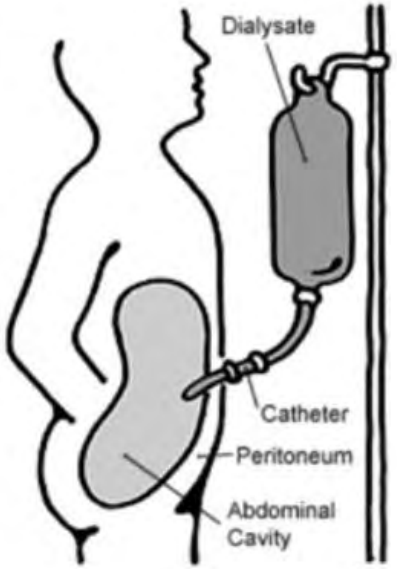



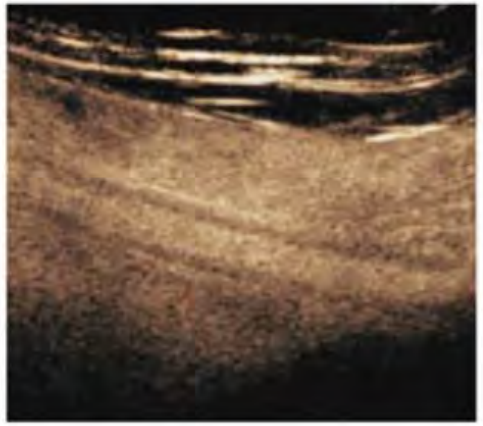

CEUS = Dynamic Functional Imaging

Catheter malfunction, Pleural communication, Leakage, Hernia

SonoVue 1.2–2.4 ml aggiunto a 10 ml Fisiologica in siringa

J Nephrol 2022, Granata & Zeiler

Diagnostica – Ecografia - CEUS

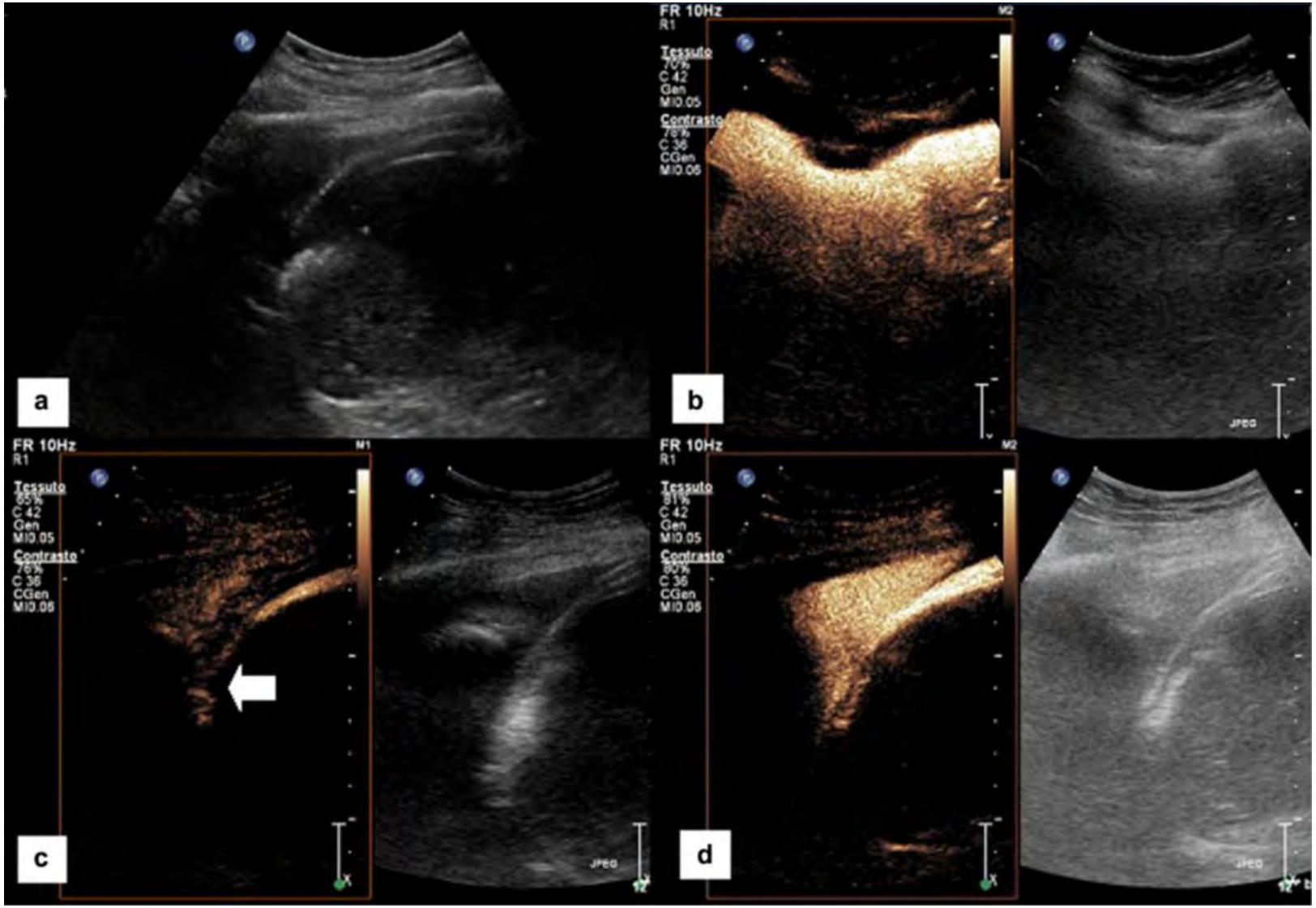

Comunicazione Pleuro-peritoneale

Il mezzo di contrasto intraperitoneale (b) attraversa il diaframma ed appare nello spazio pleurico (c + d)

J Nephrol 2022, Granata & Zeiler

Diagnostica – Ecografia - CEUS

Successful Diagnosis and Treatment of Peritoneal Dialysis-Related Pleuroperitoneal Communication by Contrast-Enhanced Ultrasonography and Thoracoscopic Surgery

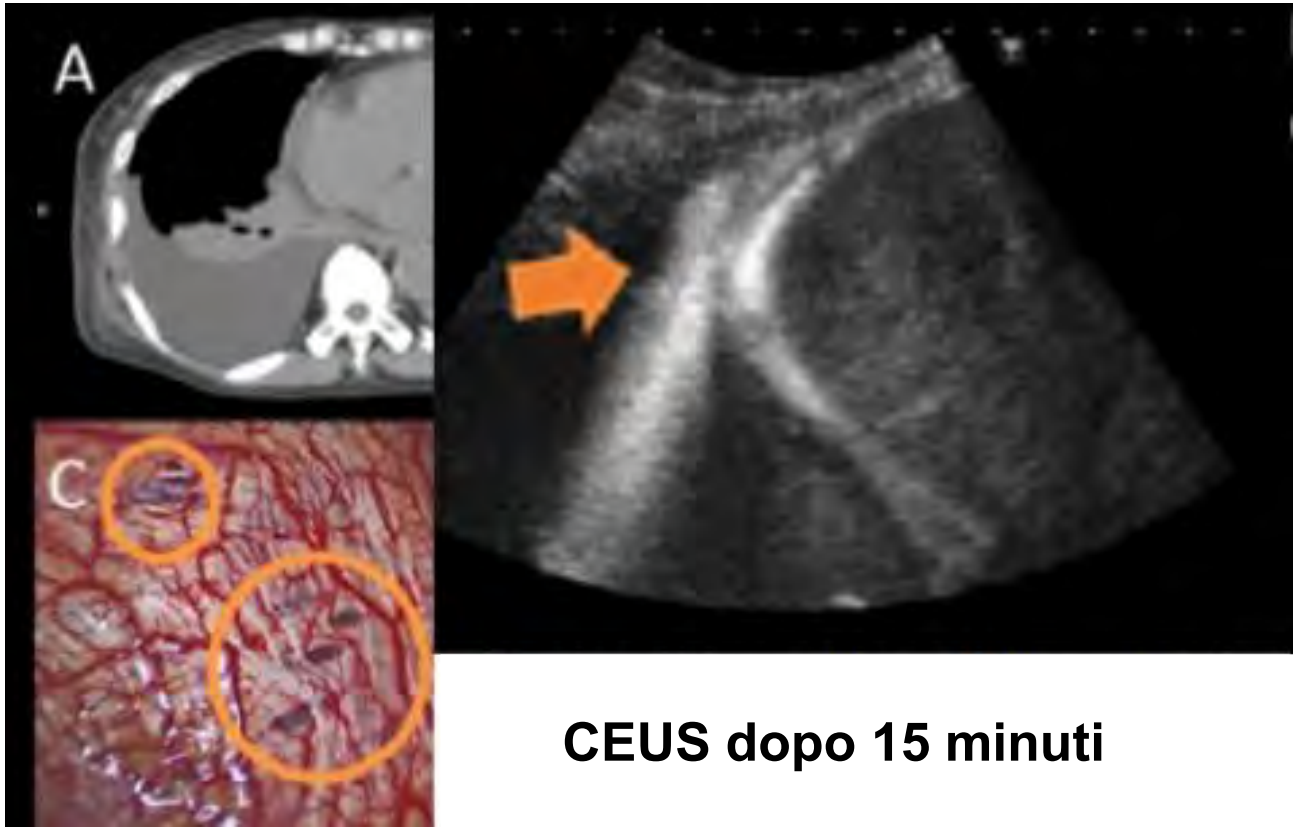

CEUS dopo 15 minuti

Perit Dial Int 2017, Matsumura

CEUS (contrast enhanced ultrasound) nella dialisi peritoneale complicata da idrotorace.

G Ital Nefrol 2017, Prencipe

Diagnostica – Ecografia

The ~~Underrated~~ Role of Ultrasound in Peritoneal Dialysis

J Ultrasound Med 2021, Granata & Zeiler

Exit site
Cuffs
Tunnel
Infection

Abdominal wall
Hernia, Leakage, Adhesions
Peritoneal-pleural defects
Catheter malfunction

Preoperative evaluation
Catheter placement

Diagnosis → **Therapeutical decision** → **Follow-up**

Diagnostica - Laboratorio

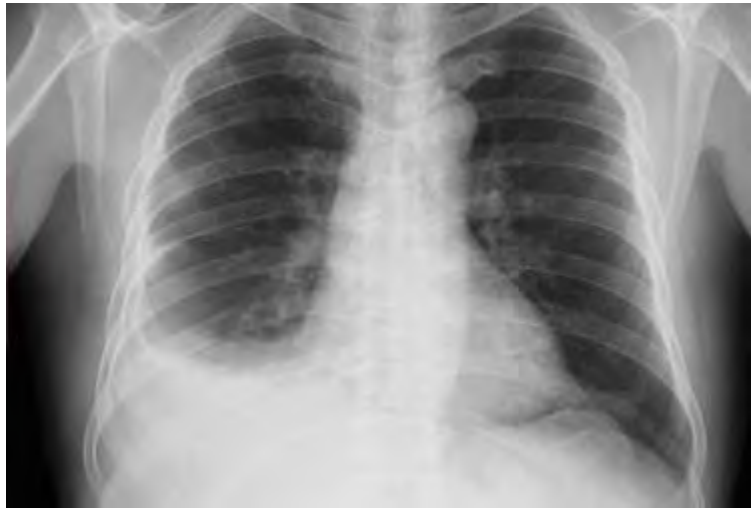

Carico con sacca Glucosio 3.86%
per almeno 4 ore prima del prelievo

↓

Svuotare l'addome

↓

Prelievo:
Glucosio plasmatico
Glucosio liquido pleurico (toracentesi)

↓

Delta Glucosio (pleura – plasma) >50mg/dl

100% specifico e 100% sensibile
per comunicazione

Diagnostica – Tomografia Computerizzata

Esame preoperatorio:

- per ernie di maggiore estensione con contenuto intestinale nel sacco erniario.
- per casi con leakage di origine non definito dall'esame ecografico

TC addome con mdc e.v. per valutare la perfusione dell'ansa incarcerata

TC peritoneografia:

- mezzo di contrasto non-ionico, contenente iodio Iopidamidolo 300mg/ml:
  100ml per 1.5 – 2 litri di dialisato
- Carico con dialisato (volume massimale tollerato)
- mobilizzazione del paziente con addome pieno
- attesa per 2-3 ore prima della TC addome

Diagnostica: TC addome

senza mezzo di contrasto

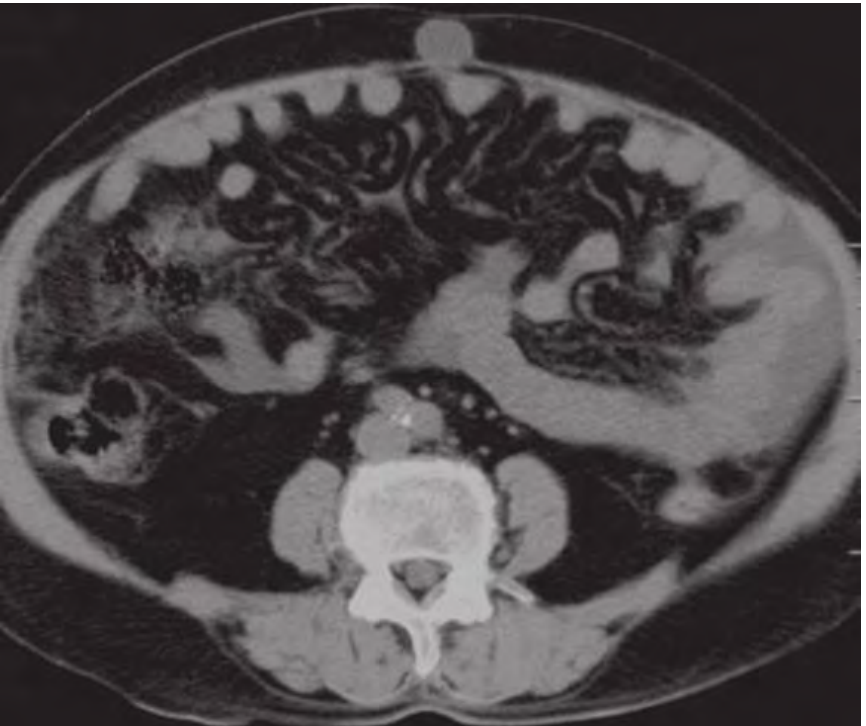

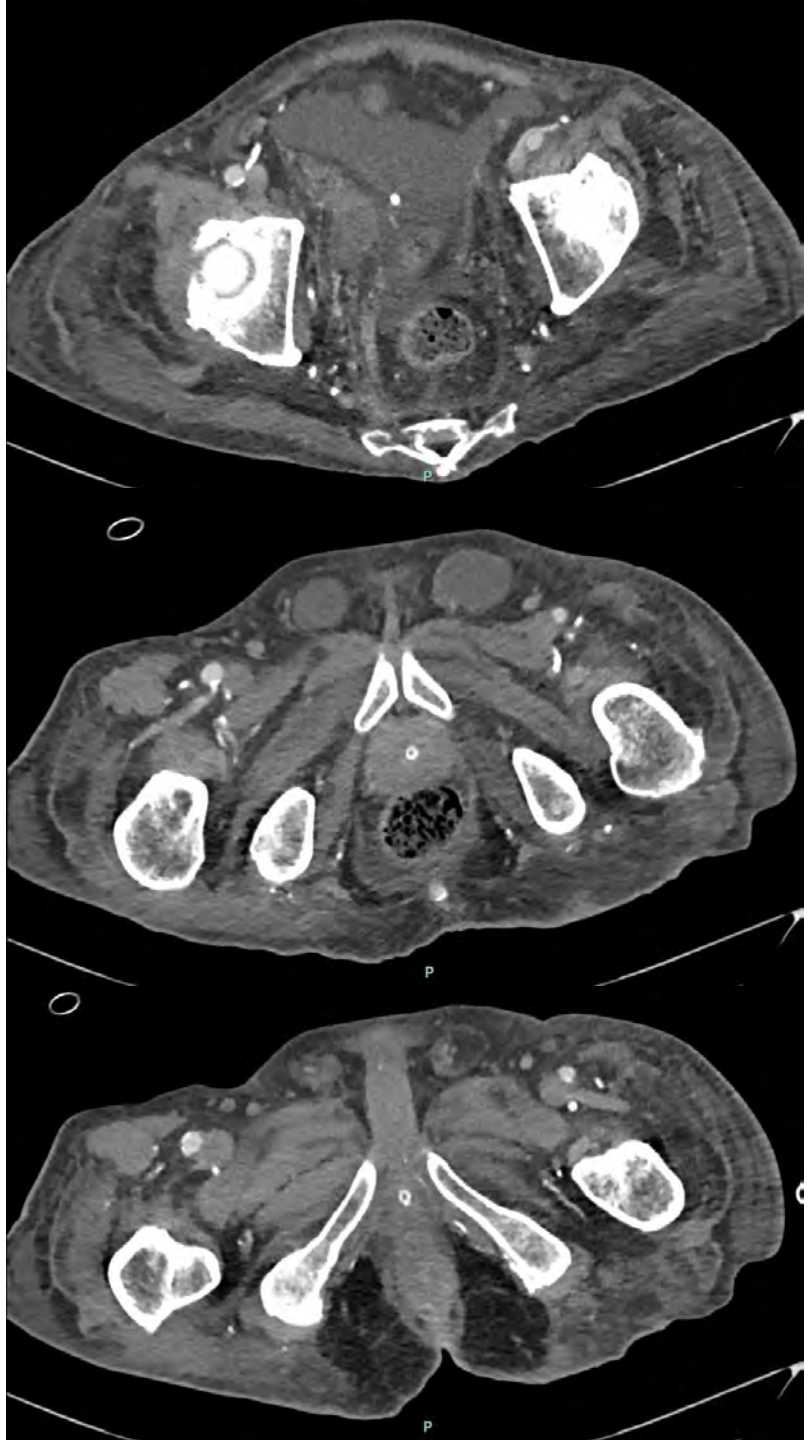

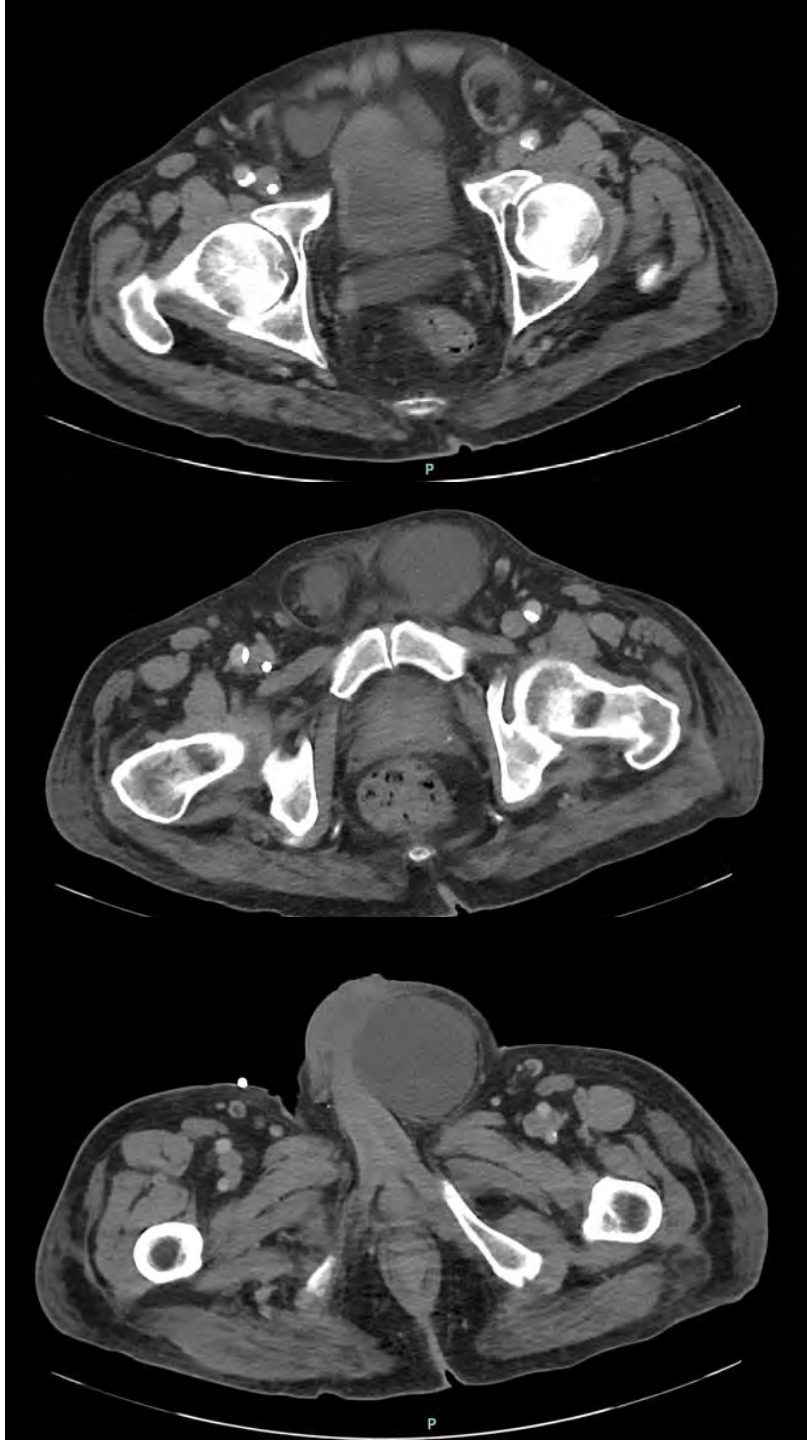

Diagnostica – TC peritoneografia

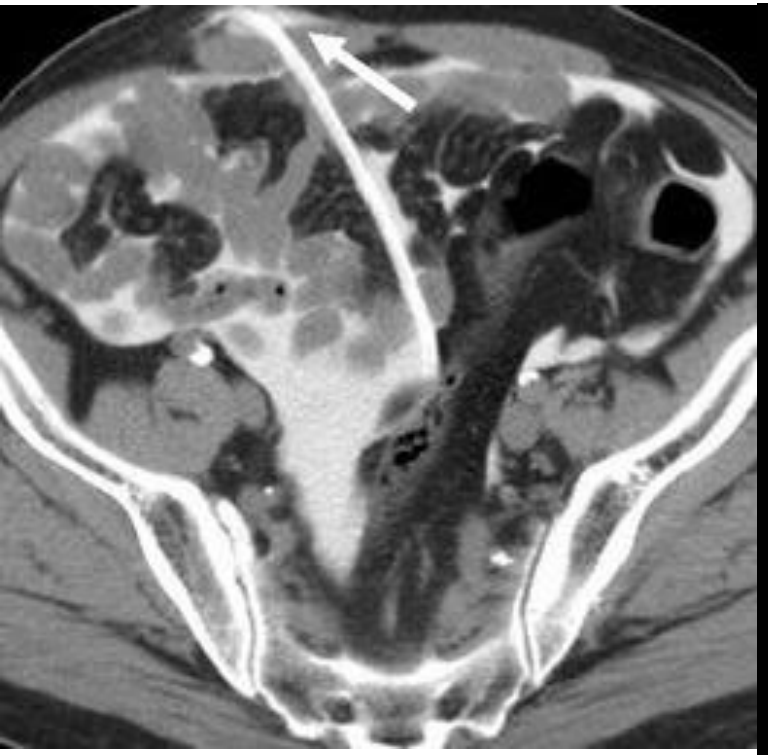

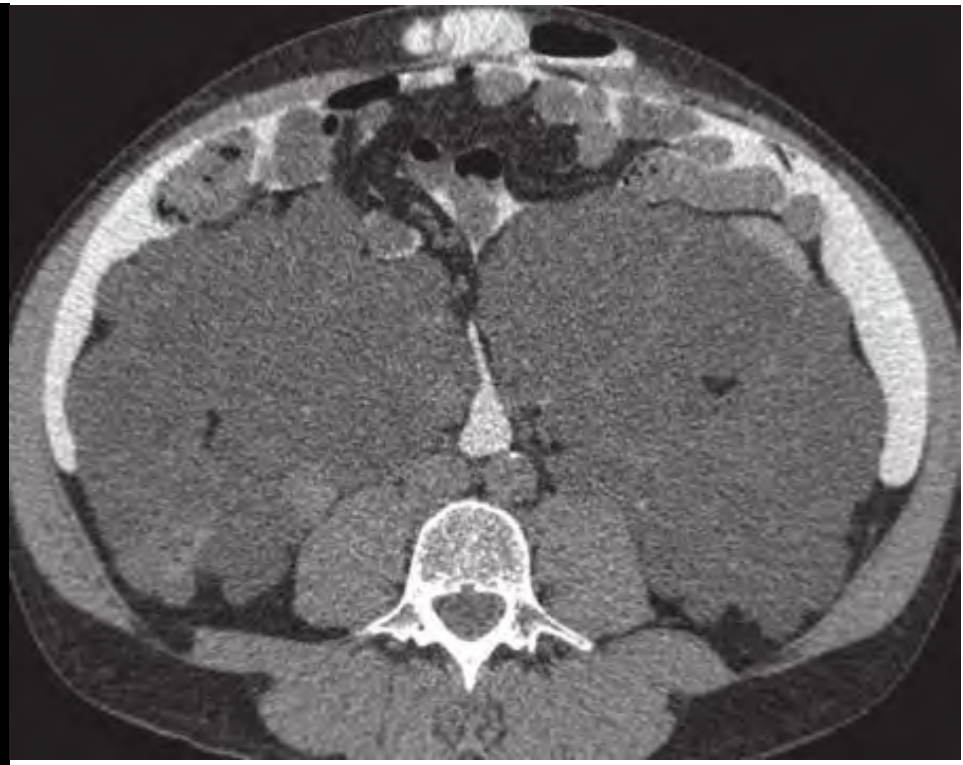

Radiographics 2009
Dtsch Med Wochenschr 2011

Diagnostica – RM addome peritoneografia

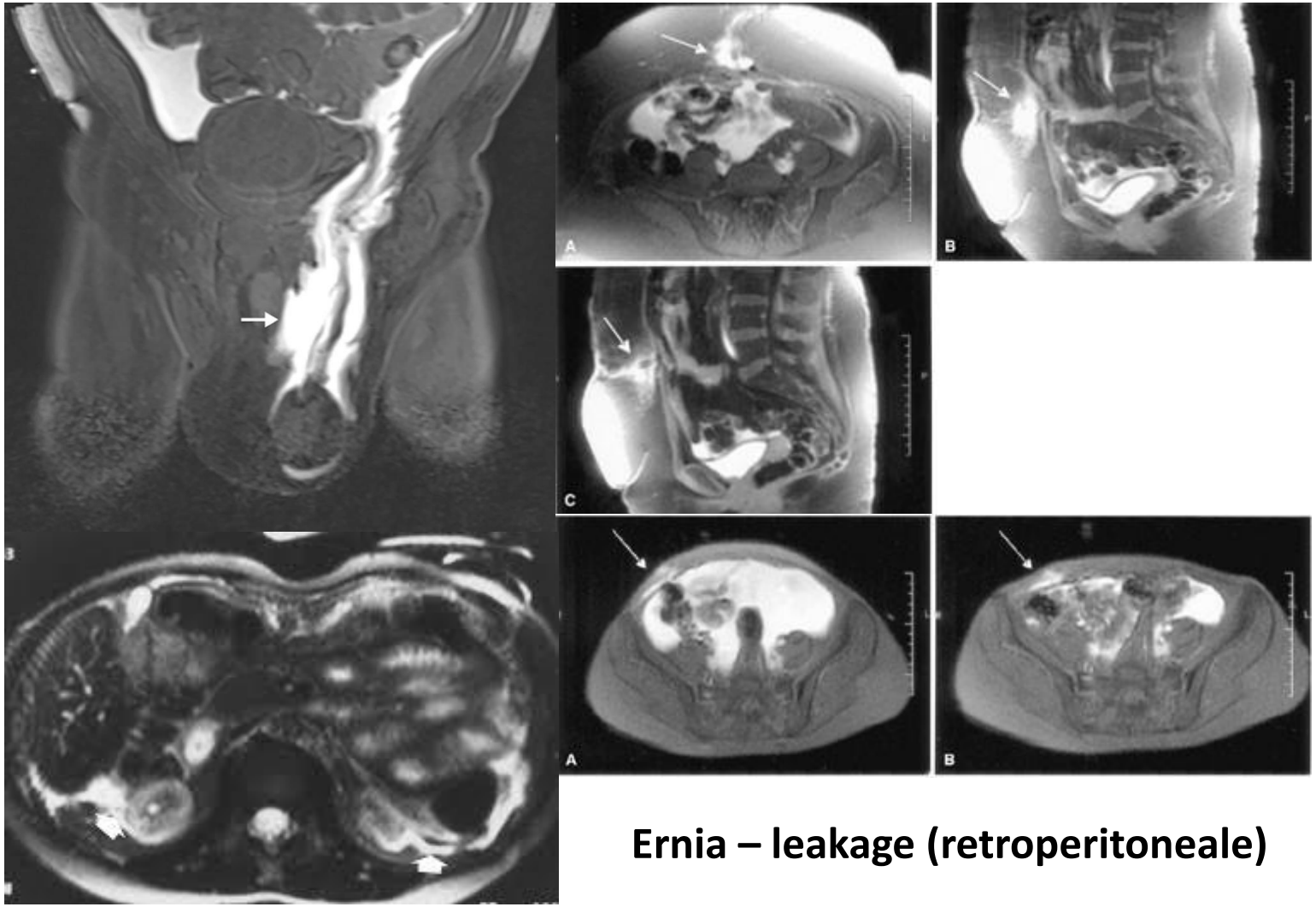

Ernia – leakage (retroperitoneale)

Senza mezzo di contrasto contenete gadolinio

Dialisato intraperitoneale come «mezzo di contrasto»

Con mezzo di contrasto contenente Gadolinio

Dialisato con 20ml Gadodiamide (Omniscan) o Gadopentetata dimeglumina (Magnevist)
in 2000ml dialisato
Mobilizzazione ed attesa per 20-30 minuti

AJR 2020
Abdominal Radiol 2005

Diagnostica - Scintigrafia

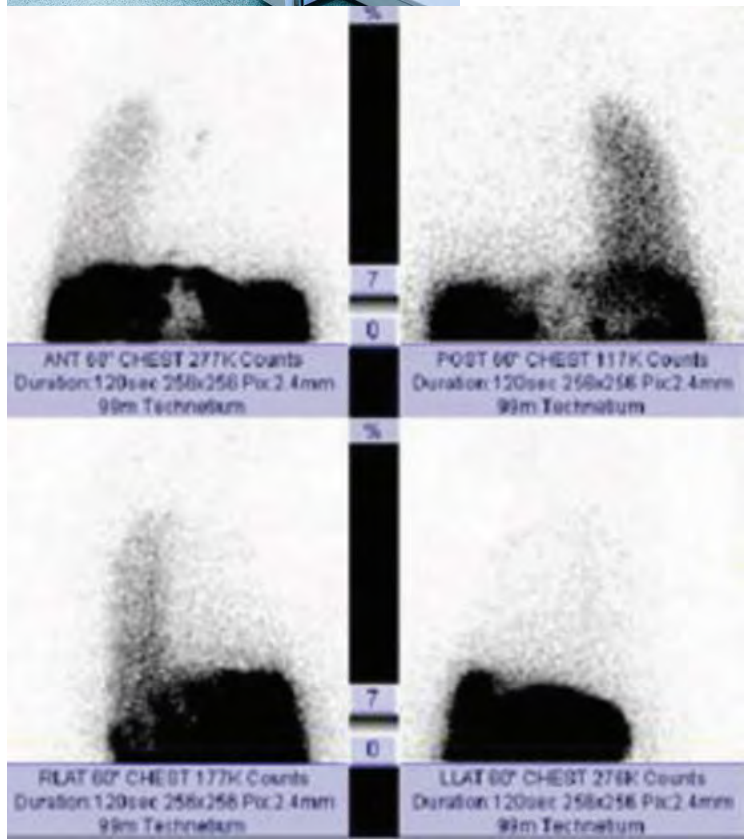

Ha perso importanza con il miglioramento della tecnologia della tomografia computerizzata

99m Tc (emivita 6 ore)

In confronto alla TC peritoneografia:

- ridotta risoluzione spaziale
- ridotta dose di radiazioni
- migliore sensitività per comunicazione pleuro-peritoneale
(sensitività: Scinti 40-50%, TC peritoneografia 33%)

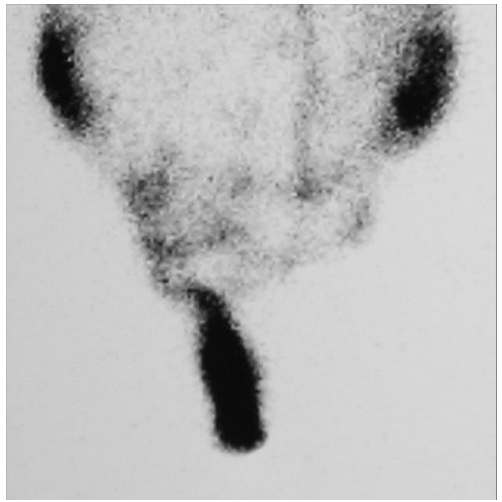

Diagnostica – Laparoscopia

Durante l'intervento di posizionamento del catetere peritoneale in laparoscopia

Home > Surgical Endoscopy > Article

The clinical implications of occult inguinal hernia identified during laparoscopic peritoneal dialysis catheter insertion

Published: 13 November 2023
Volume 38, pages 186–192, (2024) Cite this article

Masashi Tsunematsu, Keigo Nakashima, Junji Takahashi, Takashi Aida, Teppei Kamada, Toru Ikegami, Naoki Washida & Yutaka Suzuki

EHS INGUINO-FEMORAL CLASSIFICATION

P = primary hernia
R = recurrent hernia

0 = no hernia detectable
1 = < 1,5 cm (one finger)
2 = < 3 cm (two fingers)
3 = > 3 cm (more than two fingers)
x = not investigated

L = lateral/ indirect hernia
M = medial/ direct hernia
F = Femoral hernia

		P	R		
	0	1	2	3	x
L					
M					
F					

Methods

This study included 79 patients who underwent initial laparoscopic PD catheter insertion between 2021 and 2022. An occult hernia was defined as an internal hernial sac of all sizes that was not detectable on physical examination. The European Hernia Society groin hernia classification was used to describe the hernia type. We investigated the association between event-free survival and occult inguinal hernias in patients undergoing PD.

Results

Occult inguinal hernias were diagnosed in 24 (32%) patients. Among these patients, 5 (21%) patients underwent metachronous repair. In patients with L2 occult hernias, the cumulative incidence rates of right and left symptomatic hernias within one year were 100% and 50%, respectively. Multivariate analysis revealed that L2 occult hernias were associated with metachronous hernia repair.

Conclusion

The L2 occult inguinal hernia during PD was associated with metachronous repair, suggesting the importance of routine examination of inguinal hernias during laparoscopic PD catheter insertion.

Surg Endosc 2024

Approccio diagnostico

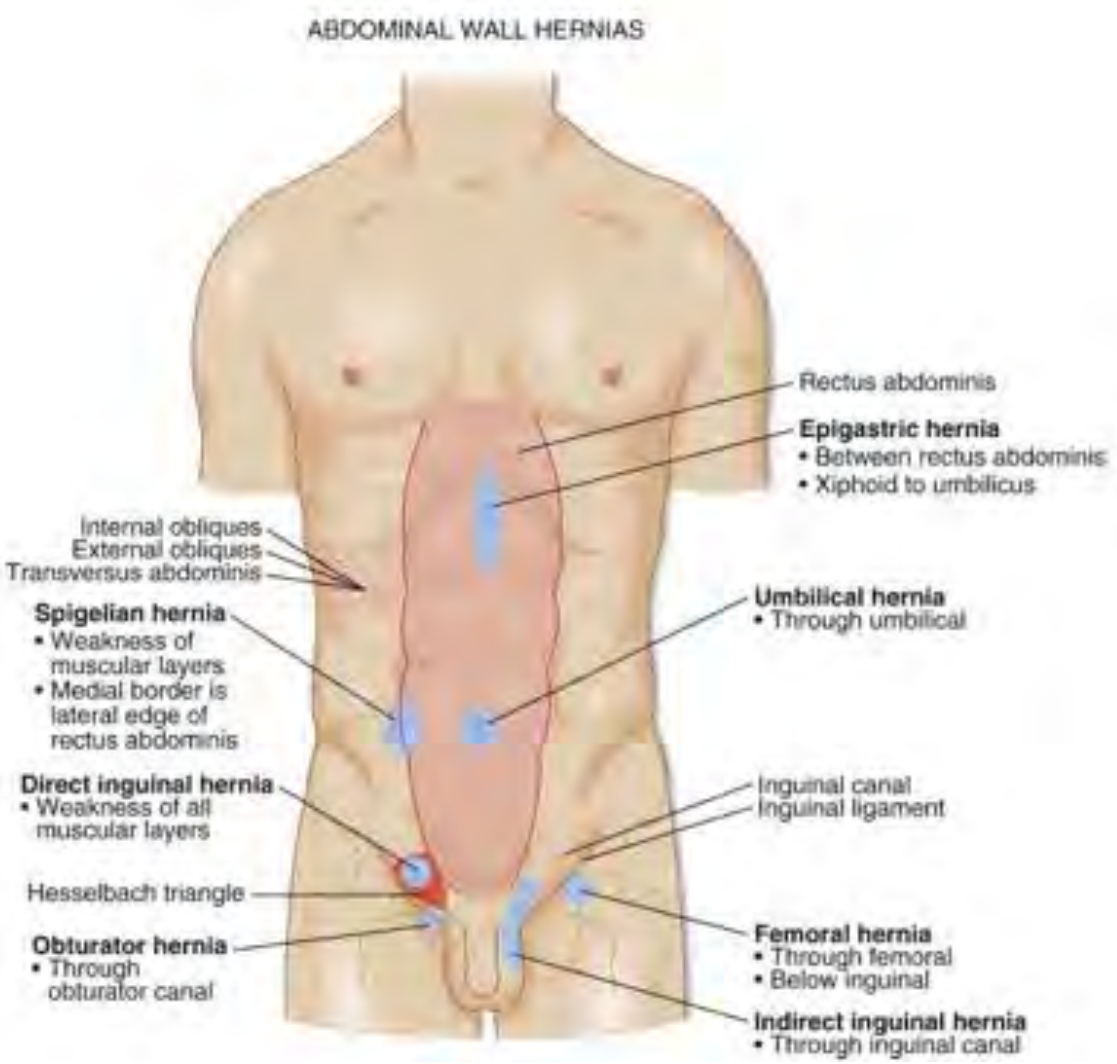

Palpazione

Foro ?

Reponibile ?

Valsalva ?

Dolore ?

Eritema – Edema ?

Ecografia +/- CEUS

Prelievo liquido

TC-Addome / peritoneografia

(RM addome, Scintigrafia)

Intervento

Terapia – Approccio conservativo

<u>In assenza di complicanze (dolore, ernia strozzata, edema, dispnea)</u>

Modificare CAPD in APD notturna

Riduzione dei volumi di carico

Stop temporaneo di dialisi peritoneale

Attendere …per settimane, **Sperare** …per qualche settimana, **Ricontrollare** …frequentemente

Terapia – Approccio interventistico

Presenza di complicanze (dolore, ernia strozzata, dispnea, edema)

Ernia ombelicale (non riponibile) già presente antecedente alla PD

Ernia inguinale già presente antecedente alla PD

Ernie riscontrate durante il posizionamento laparoscopico del catetere peritoneale

Insuccesso della terapia conservativa

Terapia – Ernie - Approccio chirurgico

senza rete «non-mesh»

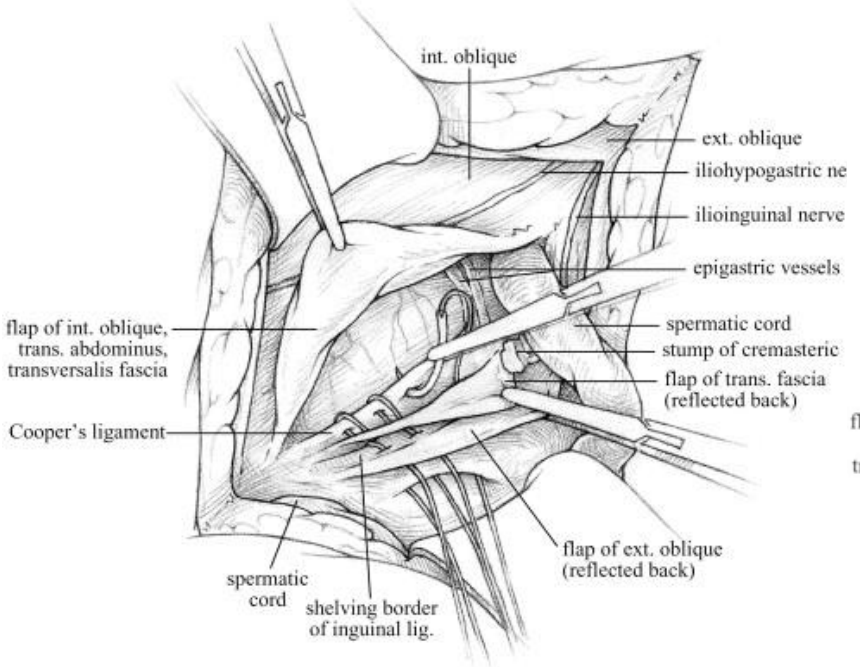

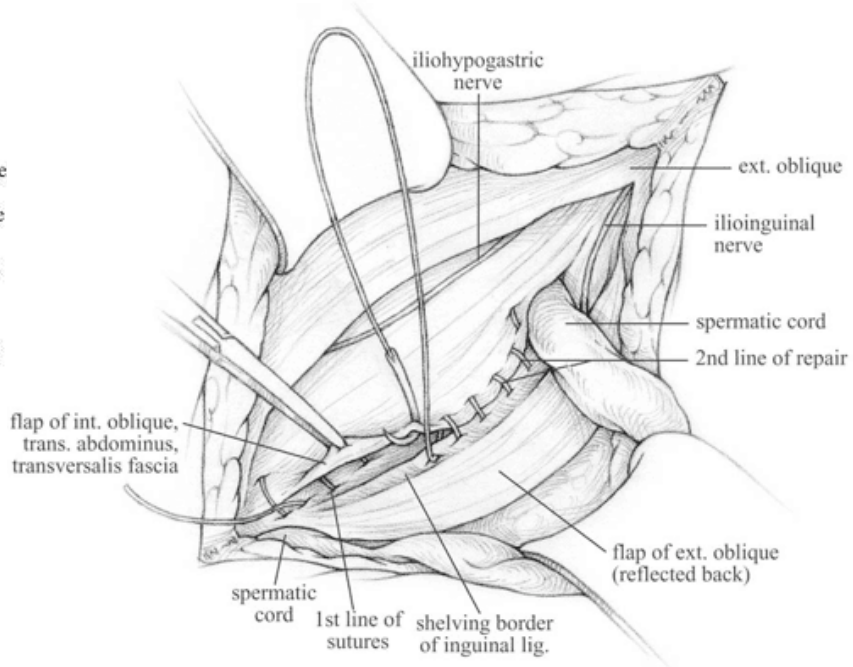

con rete «tension-free mesh»

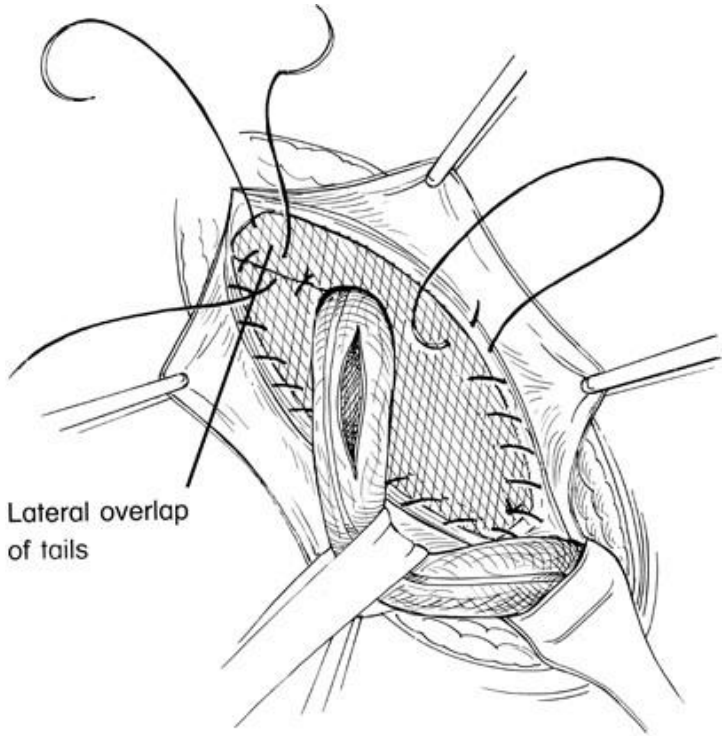

Risultati migliori con rete, ripresa PD possibile anche dopo 1-2 giorni (APD 1000ml volume di carico)

Terapia – Ernie - Approccio chirurgico

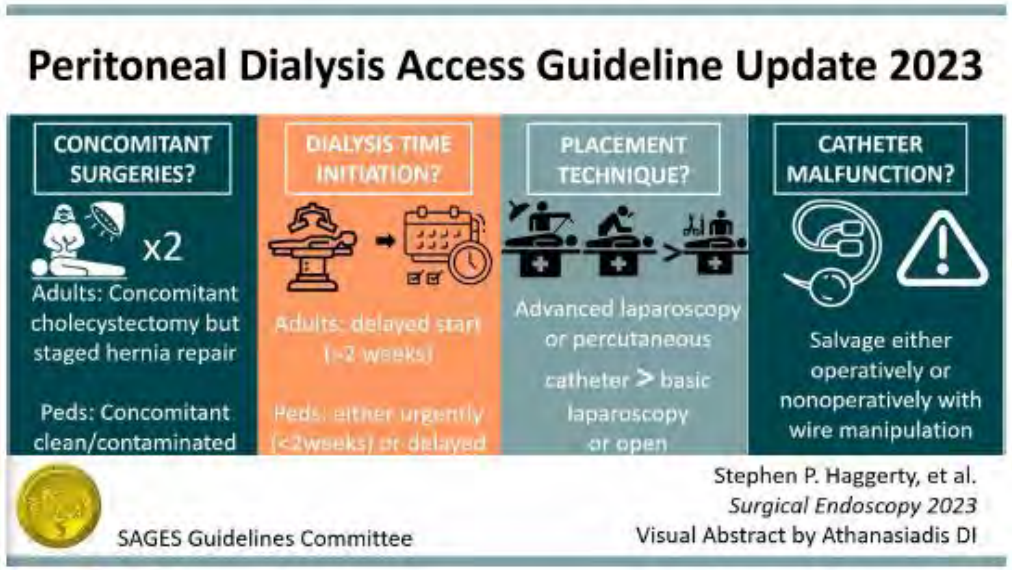

Recommendations

KQ1. In adult patients needing both renal replacement therapy and hernia repair, should hernia repair be performed concurrently with peritoneal dialysis catheter placement or be staged?

The panel suggests staged hernia repair and peritoneal dialysis catheter placement rather than simultaneous operations for adults needing both renal replacement therapy and hernia repair (conditional recommendation, very low certainty evidence).

Terapia – Ernie
Approccio chirurgico

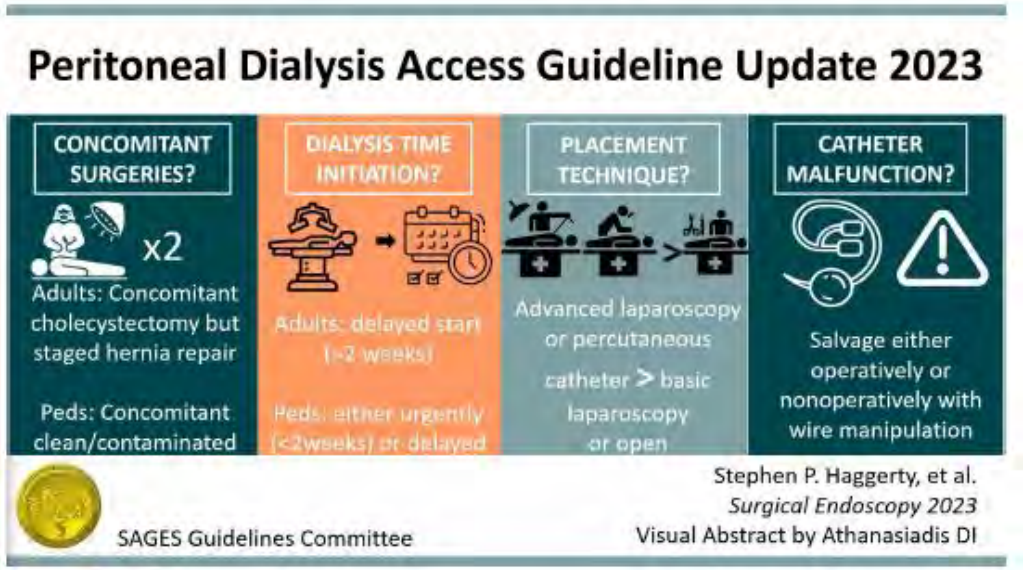

Benefits

Based on the evidence the desirable effects of staged repair are lower incidence of bleeding, dialysate leak, and peritonitis. The favorable effects of staged repair were judged to be moderate in magnitude.

- Bleeding: Staged repair event rate of 1.6% in 2 studies [33, 34] vs simultaneous repair event rate of 2.8% in 1 study [33].
- Dialysate leak: Staged repair event rate of 3.8% (range 1.5%-10.0%) in 2 studies [28, 32] vs simultaneous repair event rate of 10.4% (range 2.8%-17.4%) in 5 studies [28, 32, 35, 37, 39].
- Peritonitis: Staged repair event rate of 6.4% in 1 study [34] vs simultaneous repair event rate of 35.7% (range 14.3%-52.2%) in 2 studies [35, 36].

Harms and burdens

With regards to undesirable effects, early catheter dysfunction, early hernia recurrence, late hernia recurrence, and mortality were similar. However the difference in rates of exit site infection were quite different. This was deemed a small effect favoring simultaneous repair.

- Early catheter dysfunction: Staged repair event rate of 4.8% in 1 study [38] vs simultaneous repair event rate of 2.3% in 1 study [40].
- Early hernia recurrence: Staged repair event rate of 4.0% (range 1.6%-10.0%) in 4 studies [28, 31, 33, 38] vs simultaneous repair event rate of 3.0% (range 2.1%-6.3%) in 5 studies [28, 33, 36, 37, 40].
- Late hernia recurrence: Staged repair event rate of 9.8% (range 2.3%-11.1%) in 4 studies [28, 31, 33, 38] vs simultaneous repair event rate of 7.1% (range 2.1%-21.8%) in 5 studies [28, 33, 36, 37, 40].
- Exit site infection: Staged repair event rate of 10.0% in 1 study [28] vs simultaneous repair event rate of 4.1% (range 3.1%-4.8%) in 2 studies [28, 40].
- Mortality: Staged repair event rate of 5.3% (range 1.6%-10.0%) in 4 studies [28, 33, 34, 38] vs simultaneous repair event rate of 2.2% (range 1.2%-16.7%) in 7 studies [28, 33, 35, 36, 39-41].

Terapia – Ernie - Approccio laparoscopico

EuraHS terminology of mesh positions during ventral hernia repair

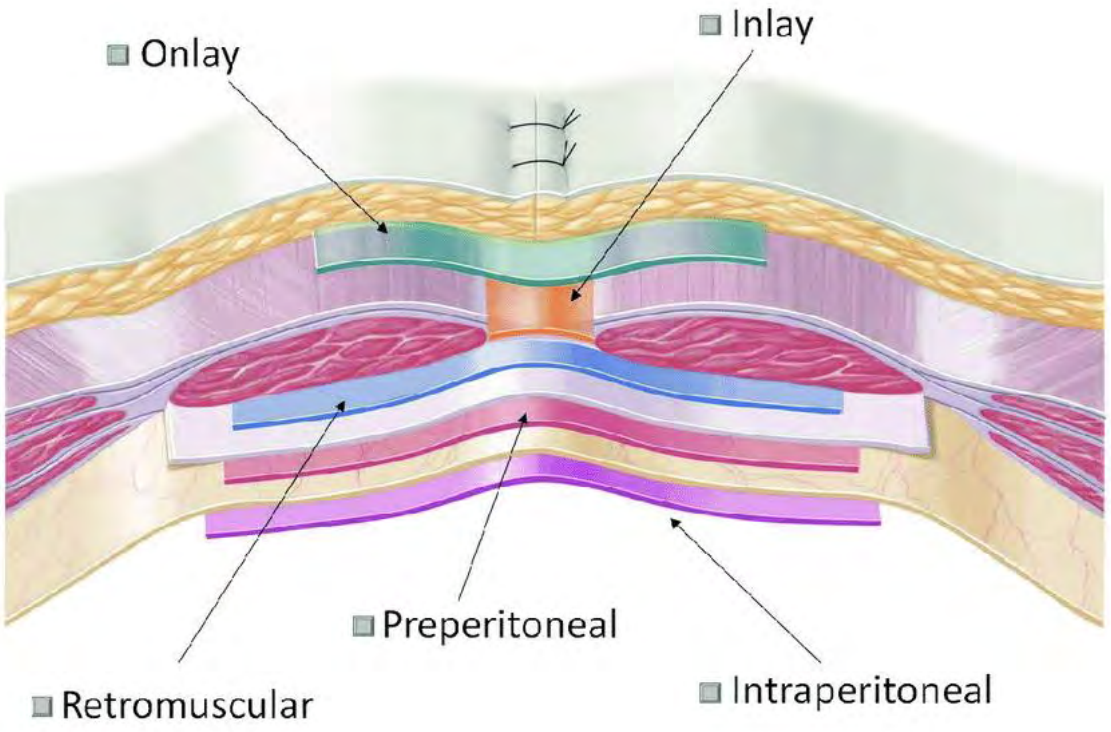

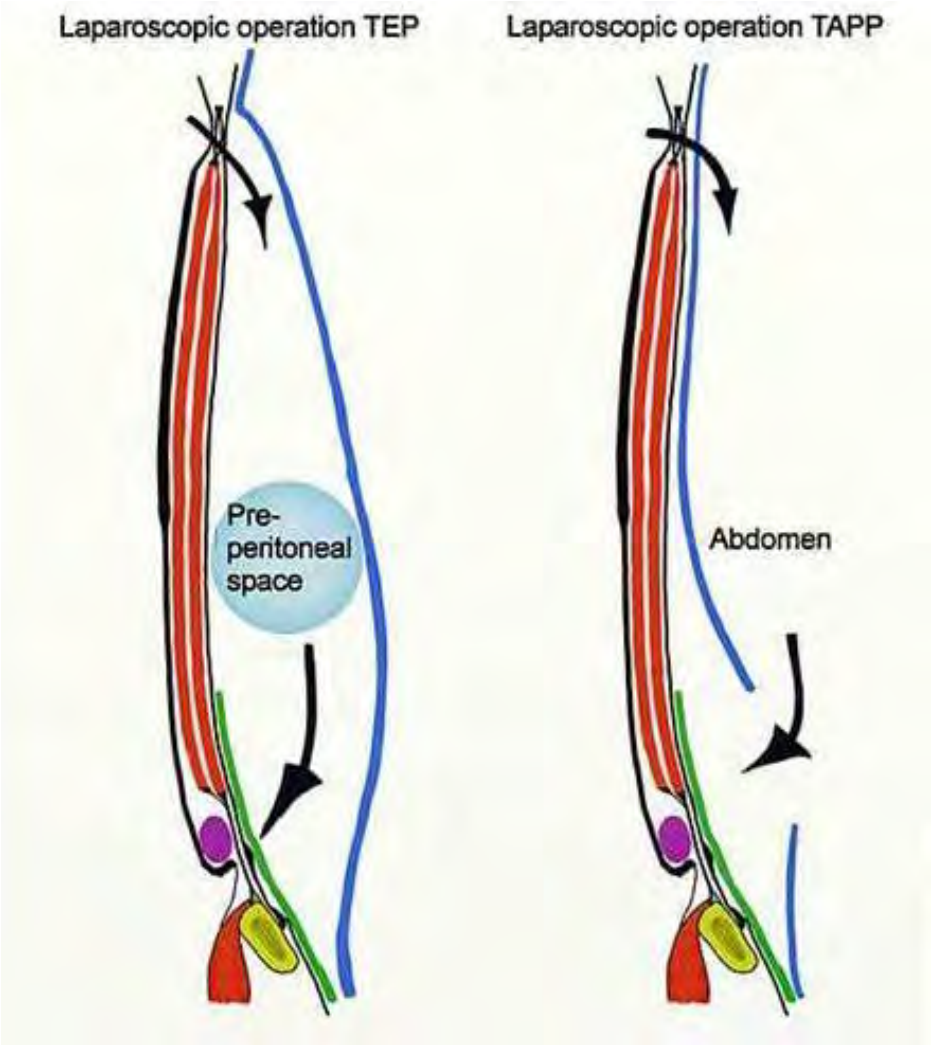

In PD non far posizionare la rete intra-peritoneale !!

Rischio di infezione della rete in caso di peritonite !!

TEP = **T**otal **E**xtra **P**eritoneal
TAP = **T**rans **A**bdominal **P**re-**P**eritoneal

Terapia – Ernie – Approccio laparoscopico

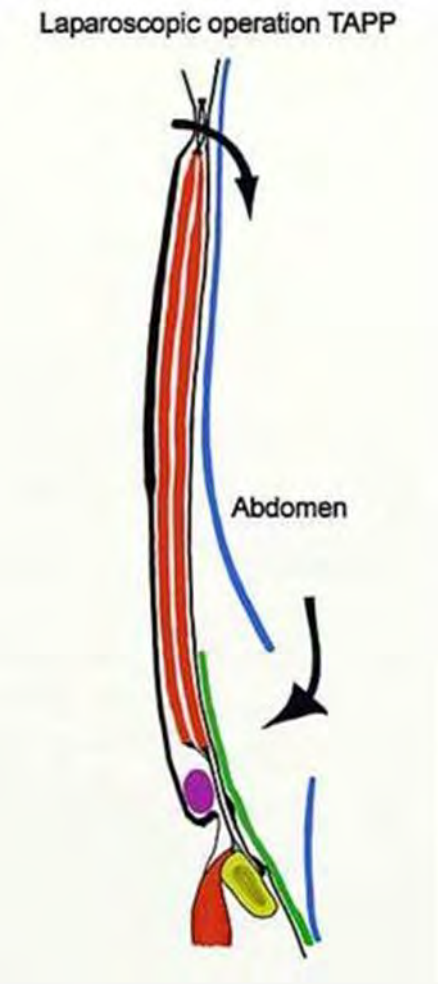

TAPP (Trans **A**bdominal **P**re-**P**eritoneal**) chirurgia laparoscopica in PD**

J Laparoendosc Adv Surg Tech A. 2023 (China)	41 pazienti, ernia inguinale nessun recidiva, 1x incisional hernia
JSLS 2023 (Saudi Arabia)	12 pazienti, ernia inguinale inizio PD con 400-600ml nessun leakage, nessun recidiva
J Laparoendosc Adv Surg Tech 2023 (China)	15 pazienti, ernia inguinale inizio PD entro una settimana nessun leakage

Terapia – Comunicazione pleuro-peritoneale
Approcio interventistico

Pleurodesi

con tetraciclina, talco, sangue autologo	*dolore, rischio di infezione* *posizionamento di drenaggio* *alto rischio di insuccesso*

Visual-assisted thoracoscopy VATS

fibrina, clips metallici, mesh/rete, pleurodesis	*anestesia generale* *posizionamento di drenaggio* *apparentemente buon successo*

Laparoscopia

fibrina, clips metallici, (mesh/rete)	*anestesia generale* *da provare*

Ernia - Leakage

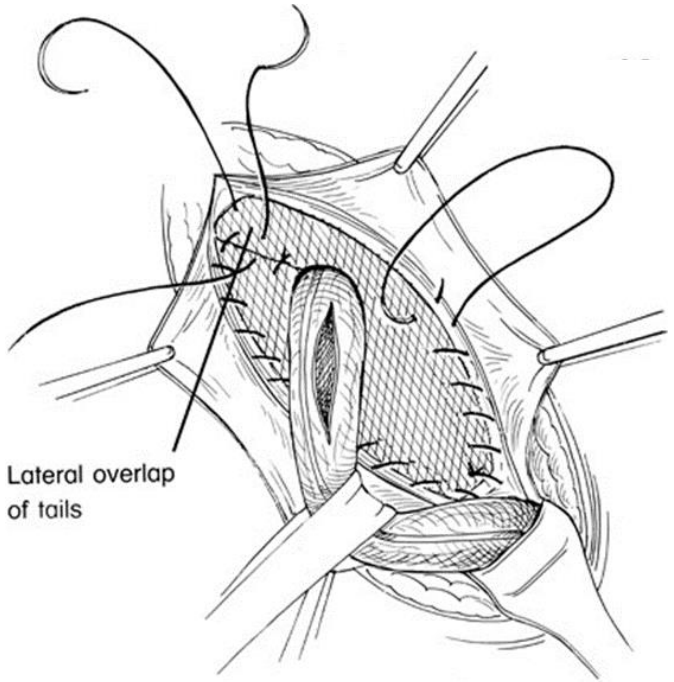

Collaborazione

Nefrologia - Radiologia - Medicina nucleare - Pneumologia - Chirurgia

Diagnostica

Banksy, street art 2004

DUXING

WHAT ARE
YOU
LOOKING AT?

BANKSY